

CORTICOTOMY-ASSISTED ORTHODONTICS

A thesis submitted in partial fulfilment of the requirements for the degree of
Doctor of Clinical Dentistry (Orthodontics)

by

Dr. Nida Khan
BDS (Hons)



Orthodontics
School of Dentistry
Faculty of Health Sciences
The University of Adelaide

2015

1. Table of Contents

Table of Contents

1. CONTENTS	2
Literature Review List of figures	4
Article One List of figures.....	4
Article One List of tables.....	4
Article Two List of figures	4
Article Two List of tables.....	4
2. ACKNOWLEDGEMENTS.....	5
3. SIGNED STATEMENT.....	6
4. SUMMARY	7
5. LITERATURE REVIEW.....	9
Introduction	9
The Periodontium.....	9
Alveolar Bone.....	9
Periodontal Ligament	11
Cementum	12
Gingiva	12
Theories of Orthodontic Tooth Movement	13
The Pressure-Tension Theory	13
Bioelectrical Theory	15
Phases of Orthodontic Tooth Movement.....	15
Accelerating Orthodontic Tooth Movement	18
Non-surgical Methods	18
Surgical Methods	21
Corticotomy Assisted Orthodontic Tooth Movement	23
Regional Acceleratory Phenomena.....	25
Animal Research	27
Human Research.....	29
Orthodontically Induced Inflammatory Root Resorption	32
Cellular Processes	33
Classification and Detection	34

Diagnosis.....	34
Microcomputed Tomography.....	35
The Animal Model	36
References.....	38
6. RATIONALE OF THE CURRENT STUDY.....	47
7. STATEMENT OF PURPOSE	49
8. ARTICLE ONE.....	50
9. ARTICLE TWO	69
10. CONCLUDING REMARKS	85

Literature Review List of Figures

Figure 1 Technique for Dentoalveolar distraction (Kharkar et al. 2010)	22
Figure 2 Acceleratory effects of RAP (Frost 1989).....	26

Article One List of Figures

Figure 1: Timeline of experimental procedure	54
Figure 2: Control and experimental groups	54
Figure 3: Appliance Design	55
Figure 4: Reflection full thickness flap.....	56
Figure 5: Corticotomy procedure being undertaken	57
Figure 6: Slice representing measure from CEJ to root apex	58
Figure 7: Sample slice of region of interest of the mesio-buccal root of the first molar	59
Figure 8: Line graph representing inter-scan differences of the same hydroxyapatite standards due to changes in time and orientation of standard.....	60
Figure 9: Reconstruction of the sagittal slices generated a 3D representation of entire root structure.....	60
Figure 10: Sample representation of roots in each group from reconstructed sagittal slices ..	61
Figure 11 Adjusted mean root volumes.	62

Article One List of Tables

Table 1: P-values when comparing root volumes between groups.....	63
---	----

Article Two List of Figures

Figure 1: Timeline of experimental procedure	73
Figure 2: Appliance Design	73
Figure 3: Corticotomy procedure being undertaken	74
Figure 4: 3D surface rendering of corticotomy cuts	75
Figure 5: Sample slice of region of interest of root of first molar	76
Figure 6: Line graph representing inter-scan differences of the same hydroxyapatite standards due to changes in time and orientation of standard.....	77
Figure 7: 3D reconstructed images of representative sample of root structures for each group	78
Figure 8: Adjusted mean values for root volume.....	79

Article Two List of Tables

Table 1: P-values when comparing root volumes between groups.....	79
---	----

2. Acknowledgements

The completion of this thesis would not be possible without the assistance of the following people:

- My supervisors, Professor Wayne Sampson, Professor Craig Dreyer, and Dr Ian Parkinson, for giving me this opportunity, providing expert guidance, editorial opinion and invaluable support.
- Bone and Joint Research Laboratory Staff – Ms Helen Tsangari, Yolandi Starczak, and Dr Paul Anderson, for their generosity with time and laboratory assistance.
- Laboratory staff at The University of Adelaide, orthodontic department, Ms Marjorie Quinn and Ms Sandie Hughes, for technical assistance.
- Ms Suzanne Edwards, for assistance with statistical analysis and interpretation.
- My fellow researchers and friends, Drs Mun Jong, Cherry Zaw and Berna Kim.
- The Australian Society of Orthodontics Research Foundation, for financial support.
- Gunz, GAC and 3M, for generous donations of materials.
- The staff of the Animal House, for their assistance with live handling of animals.
- To all my wonderful friends, who have made me laugh, cry and held me together over last three years.

And finally, I wish to dedicate this to my beloved family, who have educated, encouraged and supported me on this journey.

3. Thesis Declaration

I certify that this work contains no material which has been accepted for the award of any other degree or diploma in my name, in any university or other tertiary institution and, to the best of my knowledge and belief, contains no material previously published or written by another person, except where due reference has been made in the text. In addition, I certify that no part of this work will, in the future, be used in a submission in my name, for any other degree or diploma in any university or other tertiary institution without the prior approval of the University of Adelaide and where applicable, any partner institution responsible for the joint-award of this degree.

I give consent to this copy of my thesis when deposited in the University Library, being made available for loan and photocopying, subject to the provisions of the Copyright Act 1968.

The author acknowledges that copyright of published works contained within this thesis resides with the copyright holder(s) of those works.

I also give permission for the digital version of my thesis to be made available on the web, via the University's digital research repository, the Library Search and also through web search engines, unless permission has been granted by the University to restrict access for a period of time.

Nida Khan

4. Summary

The aims of the present study were to evaluate the root structure changes in untreated and buccal orthodontic tooth movement groups, with or without adjunctive flap surgery or corticotomy in an animal model, using Micro-CT. The null hypothesis was that there are no differences in the root structure following orthodontic tooth movement, flap surgery, corticotomy or combinations of orthodontic tooth movement and surgery compared with a control group, in both experimental and contralateral sides.

Thirty six male Sprague-Dawley rats were randomly divided into six groups (three control and three experimental):

1. Nil intervention
2. Flap surgery
3. Corticotomy procedure only
4. Tooth movement only
5. Flap surgery and tooth movement
6. Corticotomy with tooth movement

The right maxillary first molar was chosen as the experimental tooth. In the tooth movement groups, a customised appliance was constructed which delivered a constant buccal force of 0.1N to the upper right first molar, over the 7 days of the experiment. In the surgery groups, a full thickness flap was raised on the buccal aspect using elevators and, in the corticotomy groups, cortical bone was perforated using a round slow speed bur. Following the corticotomy procedure, the raised flap was repositioned using a tissue glue. All animals were sacrificed seven days after appliance insertion. This was followed by dissection of the maxilla, resin embedding and Micro-CT scanning.

Micro-CT slices were assessed and the area of interest outlined. This consisted of the five roots of the maxillary right and left molar teeth from cemento-enamel junction to the apex of the tooth. Reconstructed images showed morphological root structure changes which were further quantified by volumetric analysis.

The results from reconstructed images showed changes in all three experimental groups; however, the greatest change was in the root structure in the “Tooth movement with flap” and “Tooth movement with corticotomy” groups. The three control groups showed minimal to nil macroscopic change, in both experimental and non-experimental sides. Volumetric analysis reflected changes witnessed in reconstructed images, with a statistically significant reduction in volume of root structure in the “Tooth movement with flap” and “Tooth movement with corticotomy” groups, as compared with the other four groups. When assessing the contralateral side in these groups, similar changes in morphology and volumetric analysis were found.

In conclusion, when assessing reconstructed images of corticotomy-assisted initial tooth movement in a rat model, morphological changes in root structure were evident. These changes were reflected as decreased root volume when comparing orthodontic tooth movement alone with orthodontic tooth movement with corticotomy and flap procedures. These changes were observed in both experimental and non-experimental sides.

The results suggest that, although surgical intervention in conjunction with tooth movement may reduce mineral bone density and bone fraction in these groups, and thus assist in initial phase of tooth movement, it may not prevent root resorption. Furthermore, the combination of surgical intervention and tooth movement has the capacity to cause systemic root structure changes in the rat model.

5. Literature Review

Introduction

The movement of a tooth can be either as part of a normal physiologic process or secondary to orthodontic manipulation. This requires both periodontal and alveolar bone changes, in a coupled process of resorption and formation (Frost 1994). Although bone remodelling is common to physiological and orthodontic tooth movement, the biological processes differ. Orthodontic tooth movement is, therefore, described as tooth movement after the application of appropriate force.

Corticotomy facilitated orthodontic tooth movement has been present in the literature since the mid-twentieth century; however, the recent popularisation of this technique has been driven by the Wilcko brothers, an orthodontist and periodontist team. It is believed that acceleration of orthodontic tooth movement may lead to a reduction in treatment times, replace some orthognathic surgeries, reduce the need for extraction, provide more bony support and decrease the rate of relapse and root resorption (Wilcko et al. 2001; Wilcko et al. 2008; Wilcko et al. 2009).

However, to date, minimal biological research into this technique exists and, therefore, it is not possible to ascertain its validity. A better understanding of the biological basis behind corticotomy-assisted orthodontics will allow the clinician to make better clinical judgements and lead to evidence-based practice.

The Periodontium

The periodontium is comprised of connective tissue which provides support for the tooth and originates from the ectomesenchyme of the first branchial arch. It is a highly vascular and unique structure, consisting of the alveolar bone, gingiva, the periodontal ligament, and root cementum. According to age, function, morphology and the oral environment, it is able to undergo change (Lindhe et al. 2009).

Alveolar Bone

The alveolar process is the thickened ridge of bone that contains the tooth sockets within the maxillae and mandibular bones. It develops during the eruption of teeth and is derived from the embryonic dental follicle. The bone in this area primarily functions to distribute and resorb forces from mastication, and other contacts and movement (Lindhe et al. 2009).

Bone is a highly dynamic connective tissue which has the capability to remodel. Composed of both inorganic (67%) and organic components (33%), bone provides mechanical support, protection for vital organs and is a reservoir of ions (in particular calcium and phosphate) (Meghji 1992).

The inorganic components of bone include hydroxyapatite (HA), and the organic components include Type I collagen (28%) and non-collagenous proteins (5%), including osteocalcin, osteonectin, proteoglycan I and II, osteopontin, sialoprotein II and matrix-GLA protein (Nanci 2007).

Bone Remodelling

The process of bone remodelling is a specific, coupled sequence of resorption and formation to replace previously existing bone (Graber et al. 2011). Due to the action of osteoclast cells, resorption involves the removal of the mineral and organic components of the extracellular matrix. This process begins with binding of a bone resorption hormone (e.g. PGE₂) to the appropriate receptor on the osteoblast, leading to signal transduction and resultant osteoblastic response. The retraction of osteoblastic cells exposes the underlying osteoid and the production of matrix metalloproteinases (MMP's). These proteins break down the non-mineralised osteoid layer and produce soluble mediators that recruit and activate osteoclasts. Once the osteoid has been removed and the mineralised matrix exposed, the activated osteoclasts can then resorb the exposed bone (Meghji 1992).

The osteoclasts, which are embedded on the bone surface in Howship's lacunae, secrete organic acids, resulting in the resorption of HA. The cell surface of the osteoclasts have a ruffled border, created by cell membrane infoldings, which results in a large surface area for exchange between the cell and bone and allows for a continuous and effective process of exocytosis and endocytosis. Enzymes, principally lysosomal enzymes, are released into the bone matrix. This produces solubilised matrix components which are engulfed into the cell, within phagosomes, for further intracellular digestion (Meghji 1992).

Bone formation involves the chemotaxis of osteoblast precursors to the site of apposition. This is followed by differentiation of precursor cells to mature osteoblasts, which synthesise and secrete the extracellular organic matrix and factors that regulate this process. Mineralisation follows the formation of the organic matrix (Meghji 1992).

Osteoclasts also play a significant role in bone formation by releasing bone-derived growth factors (BDGFs) from the extracellular mineralised matrix; these include factors such as bone morphogenic proteins (BMPs), platelet derived growth factor (PDGF), acidic and basic forms of fibroblast growth factor (aFGF, bFGF), transforming growth factor-beta (TGF-beta) and insulin-like growth factor 1 (IGF-1) (Meghji 1992).

Periodontal Ligament

The periodontal ligament (PDL) is a richly vascularised, soft, cellular connective tissue which surrounds the roots of teeth joining the root cementum with the alveolar bone proper. Consisting primarily of a collagenous fibre network, the PDL surrounds the tooth root and provides a supportive mechanism; this is believed to protect the surrounding tissues from damage. In particular, the ligament is able to redistribute and absorb force into the alveolar process and allow tooth mobility (Proffit et al. 2007; Lindhe et al. 2009).

The ligament is arranged in bundles which are organised during root development and eruption. The fibre bundles can be divided into alveolar crest, horizontal, oblique, apical and inter-radicular fibre groups. Most of the fibres are orientated in an oblique fashion and follow a wavy course, enabling the tooth to move within its socket for physiological tooth movement (Lindhe et al. 2009).

Although the fibre bundles consist primarily of collagen, elastic fibres (oxytalan, elaunin and elastin) and blood vessels are also present. The primary cell populations within the periodontal ligament are fibroblasts, osteoblasts, osteoclasts, cementoblasts, epithelial cells, inflammatory cells, nerve cells and blood vessel related cells (eg. endothelial cells) (Lindhe et al. 2009).

Cementum

Differentiating from the dental follicle, cementoblasts synthesise collagen and ground substance to form cementum. Cementum is a specialised mineralised tissue covering the surface of the root and occasionally small portions of the crown. It functions primarily to attach periodontal ligament fibres to the root and assists in repairing the tooth root after damage to its surface. Unlike bone, cementum contains no nerves, blood or lymph vessels, and does not undergo remodelling. However, increases in cementum thickness occurs via the deposition of successive layers (Bosshardt and Selvig 1997; Bosshardt 2005; Lindhe et al. 2009).

Prior to the eruption of the tooth, the cementum is formed slowly in layers. Once the tooth erupts and comes into occlusion, cementum is formed more rapidly and subsequently develops into two types, acellular and cellular (Schroeder 1986).

Acellular cementum covers the cervical third of the root and forms prior to the tooth becoming functional. In contrast, cellular cementum covers the apical two thirds of the root and is laid down adjacent to acellular cementum layer. Cellular cementum derives its name due to the incorporation of cementoblasts into the matrix during mineralisation and, once incorporated, cementoblasts are called “cementocytes”. Unlike acellular cementum, cellular cementum increases in thickness with age and can be up to 10 times the thickness of acellular cementum. Consequently, the thickness of cementum is considerably greater at the apical portion of the root (Schroeder 1986; Lindhe et al. 2009).

Secondary to functional stimuli, the resorption of cementum occurs. However, it must be noted that these stimuli are greater than those required for the initiation of bony resorption. Like bone resorption, “cementoclasts” are blood-borne multinucleated giant cells which have similar characteristics to osteoclasts. Cementoclasts reside in resorptive lacunae and have a brush border adjacent to the cementum (Lindhe et al. 2009).

Gingiva

Gingiva is the soft tissue investing the tooth crowns. Although not part of the suspensory PDL, the gingiva functions primarily to protect the underlying tissues from factors such as saliva, micro-organisms and shear stresses associated with mastication. Anatomically, gingiva can be divided into attached (that which is attached to the bone) and free (gingival margin) with thick keratinised stratified squamous epithelium, sulcular epithelium (non-keratinised stratified squamous epithelium which attaches to the tooth slightly below the most coronally visible gingival margin) and junctional epithelium (stratified squamous epithelium which prevents the content of the oral cavity from entering the tooth supporting tissues). The gingiva contains collagen fibres within the lamina propria which can be divided into five groups: transseptal, dento-periosteal, dento-gingival, circular and alveolo-gingival fibers (Nanci 2007; Lindhe et al. 2009).

Theories of Orthodontic Tooth Movement

Orthodontic tooth movement involves the application of mechanical forces to the roots of teeth and the surrounding periodontal tissue. This initiates a remodelling process which facilitates the movement of teeth through bone. Two major theories have been described in the literature; the pressure-tension theory and the bioelectric theory (Proffit et al. 2007).

The Pressure-Tension Theory

Tooth eruption was first described in terms of bone apposition and resorption by Black in 1880. This was followed by Kingsley and Farrar who suggested that tooth movement occurs not only due to alveolar bone changes but also changes within the periodontal ligament (Baumrind 1969; Graber 1976).

The pressure-tension theory relates tooth movement to cellular changes produced by chemical messengers traditionally thought to be generated by alterations in blood flow through the PDL. The changes in blood flow are thought to stimulate the periodontal cells to release chemical messengers involved in both osteoclastic and osteoblastic activity. The result is the resorption of bone on the pressure side and deposition of bone on the tension side with collagen remodelling on both sides (Graber et al. 2011).

Early histological works on orthodontic tooth movement were conducted by Sandstedt (1904, 1905). Using dogs as an experimental model, Sandstedt found deposition of bone on the tension side and alveolar bone resorption on the compression side of the tooth being moved (Meikle 2006).

On the tension side, bone spicules were found to follow the orientation of the periodontal fibre bundles and on the pressure side an abundance of multinucleate osteoclasts were found in Howship's lacunae. Sandstedt also found excessive force led to compression of the periodontal ligament, capillary thrombosis, necrosis and a resultant cell-free area, referred to as hyalinisation. Alveolar bone resorption in hyalinised zones occurs via a process of undermining resorption (Meikle 2006).

In conflict with Sandstedt's work, Oppenheim experimented on monkeys and believed that bone transformed its entire architecture following pressure, with a predominance of deposition over resorption (Meikle 2006).

Schwarz believed that these differing results were due to differing experimental design with Oppenheim describing aspects of bone bending. Schwarz suggested that teeth could only be moved within the periodontal ligament and if compression exceeded capillary blood pressure (20 Gm/cm^3) tissue necrosis through "suffocation of the strangulated periodontium" would occur. Excess force would result in the tooth undergoing resorption (Schwartz 1932; Meikle 2006).

Doubt has been cast on this theory by multiple authors, such as Gottlieb, who suggested that the contact between tooth and bone determined the limit of tooth movement (Gottlieb 1946). However, later authors such as Baumrind (1969) and Grimm (1972) showed that alveolar bone deflection and periodontal changes were frequently seen when orthodontic forces were applied to teeth.

Baumrind (1969) and Baumrind and Buck (1970), using autoradiography, found that on both tension and pressure sides, cell proliferation and metabolic activity was increased and protein synthesis decreased. Baumrind believed that "when orthodontic appliances are placed, forces delivered to the tooth are transmitted to all tissues in the region of force application", so the periodontium acted like a continuous hydrostatic system whereby a force applied will be

distributed equally to all regions. This experimental work also showed that there was greater molar displacement (up to 10 times) than there was periodontal width reduction, suggesting bone deformation upon loading.

Heller and Nanda (1979) found that the commonly held belief that periodontal fibres generate tension is unlikely to be the cause of tooth movement. By inhibiting cross-linking of collagen in a rat model, it was found that the principal fibres did not undergo significant strain or the transference of forces to the alveolar bone via Sharpey's fibres.

Bioelectrical Theory

Stress generated signals play an integral role in the general maintenance of the skeleton. Without these bone (mineral) loss due to atrophy may occur. Orally, stress-generated signals from mastication are likely to play an important role in bone maintenance and an uncertain role in orthodontic tooth movement (McDonald 1993).

The bioelectric theory proposes that tooth movement occurs due to changes in bone metabolism which is controlled by the electric signals produced when alveolar bone flexes and bends. The bending of bone causes small electrical charges. This phenomenon has been observed in the bending of dry bone and it has, therefore, been hypothesised that these signals may induce orthodontic tooth movement (Fukada and Yasuda 1957; Becker et al. 1964).

Zengo et al. (1973) believed that electrical potentials regulated osteogenesis and bone resorption. This is supported by the work of Davidovitch and colleagues who, using a feline model, demonstrated that orthodontic tooth movement could be enhanced by locally applied electric currents. Enhanced bone resorption was found near the anode (PDL compression site) and formation near the cathode (tension site) (Davidovitch et al. 1980).

Phases of Orthodontic Tooth Movement

Burstone (1962) was first to classify and describe the movement that a tooth undergoes after the application of orthodontic force. He divided this process into three phases:

- Instantaneous tooth movement
- Lag phase

- Linear or progressive tooth movement.

The initial phase is characterised by periodontal ligament displacement, bone strain and extrusion. This causes a form of rapid tooth movement which is a direct consequence of the movement of the tooth within the bony socket. This response varies due to occlusion, the width and health of the periodontal ligament, length of the tooth root and the configuration and the magnitude of force. This phase occurs within seconds and lasts approximately 5-6 days when a cessation in tooth movement occurs (Burstone 1962; Graber et al. 2011).

Following the initial phase, a lag phase ensues which sees a significant period of time in which no tooth movement occurs. During this time, cells within the bone marrow differentiate and undermining resorption occurs. Although highly variable, this phase usually takes 2-3 weeks and is directly related to the age of the patient, the density of the alveolar bone, the extent of periodontal necrosis and the frequency of force activation (Burstone 1962; Graber et al. 2011).

The majority of tooth movement occurs during the linear phase when alveolar bone remodels due to periodontal ligament widening and osteoclasts resorbing the bone. This process continues for up to 10-12 days, even without the exertion of orthodontic force (Reitan and Kvam 1971).

Overall, there is minimal tooth movement during the first two phases and, therefore, the reduction or even elimination of the lag phase would decrease the time required to achieve orthodontic tooth movement (Burstone 1962). However, using human premolar teeth, Reitan demonstrated that the reaction of tissue to orthodontic stimulus depended not only on the type and duration of the stimulus but the mechanics being utilised (tipping versus bodily movement) and on individual variation (Reitan 1957; Reitan 1964).

Increased levels of force application results in a greater reduction in blood flow in areas of compression. If an applied force is great enough to totally occlude the blood vessels, sterile necrosis occurs and an avascular area, called the hyalinisation zone, is produced.

Hyalinisation is the appearance of sterile necrotic tissue following application of orthodontic force (Schwarz 1932; Reitan 1974). Bone remodelling adjacent to the hyalinisation zone is accomplished by undermining resorption. This form of resorption causes a halt in tooth

movement, partly due to the delayed stimulation of differentiation of cells within the marrow spaces and because a considerable thickness of bone must be removed from the underside (Gianelly 1969). Other factors such as the type and magnitude of force and treatment duration are found to be associated with undermining resorption (Storey and Smith 1952; Reitan 1985; Pilon et al. 1996; von Böhl et al. 2004).

Previous studies have reported that hyalinisation appears in local pressure zones of the PDL during ‘the initial phase’ of orthodontic tooth movement. More recently, von Böhl et al. demonstrated that hyalinisation could not only be observed in the initial phase of orthodontic tooth movement but also in the later stages (during which small hyalinised patches were found) (von Böhl et al. 2004; von Böhl and Kuijpers-Jagtman 2009). This supported the findings of Kohno et al., who concluded that experimental tooth movements in rats (using light orthodontic forces of 1.2, 3.6, 6.5 and 10 gf), were almost constant or fluctuated over a cycle or several days duration. None of the experimental groups showed tooth movement similar to those in the traditional theory described by Burstone (Kohno et al. 2002).

Tomizuka et al., in a rat study, found that an initially light and gradually increasing force (delivered with magnets) resulted in greater osteoclast recruitment and less hyalinisation than a heavier initial force that increased to the same end force level (Tomizuka et al. 2007).

In a systematic review, von Böhl and Kuijpers-Jagtman (2009) concluded that most studies reporting on hyalinisation lacked homogeneity and had short experimental periods. In particular, most studies demonstrated tipping tooth movements which lead to uneven stress and strain distribution in the PDL, making hyalinisation difficult to reproduce. In addition to this, sections were often prepared parallel to the mid-sagittal plane of the tooth; however most areas of hyalinisation are not found in this plane.

Furthermore, von Böhl and Kuijpers-Jagtman (2009) reported that hyalinisation occurred earlier in the experimental phase in rats and mice, compared with other species. In part, this could be explained by the increased density of alveolar bone and less abundant osteoid layer found in rats, as compared to humans (Reitan and Kvam 1971). The narrower width of the rat PDL induces higher forces and relatively more local strain on the alveolar bone that leads to a diminished blood flow and formation of a necrotic area. Additionally, the higher rate of

bone turnover during the remodelling process in rats may contribute to the development of necrosis (Kvam 1968; Rygh 1972).

However, Pilon et al. (1996) demonstrated in dogs that the variation in the rate of tooth movement between individuals was due to variation in metabolic factors. The magnitude of force was not found to be decisive in determining the rate of bodily tooth movement but individual characteristics were. Therefore, large individual variation and inherent metabolic factors may have a greater part to play than previously thought. Individual variation in tooth movement may be due to individual variation in anatomical structure, bone/mineral density or cellular activity within the PDL and alveolar bone (von Böhl and Kuijpers-Jagtman 2009). Individual differences in the process of bone remodelling are possibly related to variation in the level of cytokines and growth factors (such as PGE 2 , IL-1 β , and TGF- β 1) which may be systemically or locally produced (Krishnan and Davidovitch 2006; Meikle 2006; von Böhl and Kuijpers-Jagtman 2009).

Accelerating Orthodontic Tooth Movement

The completion of orthodontic treatment in a timely fashion allows for less impact on patient's lifestyle, more accurate cost predictions and decreases risks such as a reduction in patient enthusiasm, root resorption and demineralisation (Sameshima and Sinclair 2001; Skidmore et al. 2006; Julien et al. 2013). Therefore, it may be favourable to increase the rate of orthodontic tooth movement through the use of non-surgical (including device assisted therapies) or surgical techniques.

Non-surgical Methods

Favourable results have been reported in the literature using a local injection of prostaglandins, vitamin D3, osteocalcin, the application of pulsed electromagnetic fields and direct electric current on the rate of orthodontic tooth movement (Davidovitch et al. 1980; Yamasaki et al. 1982; Collins and Sinclair 1988).

Prostaglandins

Yamasaki et al. demonstrated the role of prostaglandins in periodontal tissues and found the increased levels of PG resulted in increased numbers of osteoclasts in a rat model and increased continuous tooth movement in a monkey model. This work was followed with clinical application. In a split mouth study, it was found that tooth movement was faster on the experimental side (injection of PGE₁) when compared with the control tooth movement side. Although patients reported significant discomfort during injection, PGE₁ is only associated with the resorption of bone in periodontal disease and sensitisation and induction of pain receptors (Yamasaki et al. 1982; Yamasaki 1983; Yamasaki et al. 1984).

Vitamin D

The active form of Vitamin D, 1,25-dihydroxycholecalciferol (1,25D), has been associated with increased bone resorption. Collins and Sinclair (1998), in using an animal model (feline) demonstrated increased orthodontic tooth movement when 1,25D was administered by local injection, which is suggested to increase bone demineralisation rate. Despite this, the lack of research on human subjects limits the universal application of 1,25D without significant concerns.

Osteocalcin

As well as hormones and local factors, the local administration of bone matrix proteins, such as osteocalcin, have been advocated to increase orthodontic tooth movement. This is believed to be effected by increasing the activation of multinucleated cells and their associated osteoclastic activity. Hashimoto et al. (2001) and Kobayashi et al. (1998) demonstrated increased orthodontic tooth movement in a rat model after using a local administration of osteocalcin. It was believed this was due to increased recruitment of osteoclasts and TRAP-positive multinuclear cells in the early phases of tooth movement.

However, the use of drugs and hormones may lead to undesirable side effects since their mode of action may be on distant cells (systemic) and not simply confined to the alveolar region. The mode and frequency of administration may also be problematic to the patient (eg. injection)(Yamasaki et al. 1984). Currently, insufficient published data provides evidence to support their use.

Electric Currents and Electromagnetic Fields

The application of electric currents and pulsed electromagnetic fields (PEMF) have demonstrated enhanced rates of tooth movement. Davidovitch et al. (1980) demonstrated that when a force was applied simultaneously with electric currents (10-20 mA), teeth moved significantly faster than with force application alone in a feline model.

Increased levels of osteoclasts in alveolar bone and subsequent increased rate and amount of orthodontic tooth movement were observed by Stark and Sinclair (1987). They described the use of PEMF in tooth movement in a rat model over a 10-day period. It was noted that changes in serological parameters related to protein metabolism and muscle activity. Later studies by Darendeliler and colleagues, also positively promoted the role of PEMF in accelerating orthodontic tooth movement (Darendeliler et al. 1995; Darendeliler et al. 1997; Darendeliler et al. 2007).

Vibration

More recently, the use of vibration has been advocated for accelerating orthodontic tooth movement. Advocates believe that secondary to mechanical strain, without PDL damage, the vibration of the bone allows for increased RANKL expression in the PDL. Accelent (Ortho Accel Technologies®, Houston, Texas) has been marketed as a non-invasive, safe, hand-held vibrating device to be used daily; however, insufficient research exists to demonstrate its efficacy (Al-Sayagh and Salman 2014; Rubin et al. 2002; Gilsanz et al. 2006; Nishimura et al. 2008).

Light-accelerated

Light-accelerated orthodontics (LAO) or photobiomodulation involves the use of low-level light therapy (LLLT) to produce non-invasive stimulation of the dentoalveolar complex. Advocates believe that LLLT causes an upregulation of ATP production by mitochondrial cells, which elevates metabolic activity and induces remodelling of cells and accelerates tooth movement (Oron 2007). A recent multicentre clinical trial by Kua et al. (2013) found a

significant increase in the initial rate of alignment when using photobiomodulation. The authors found mean rate of change in lower incisor irregularity of 0.49 and 1.12 mm/week for the control and test groups, respectively. Other published clinical case series have also found LLLT increased velocity of tooth movement and decreased pain (Sousa et al. 2011; Cruz et al. 2004)

Gene Therapy

The use of gene therapy has also been advocated by some authors, in preference to surgical techniques (Iglesias-Linares et al. 2011). Kanzaki et al. found favourable results when using local RANKL gene transfer into the periodontal tissue in a rat model to accelerate tooth movement and local gene transfer of OPG to inhibit tooth movement (Kanzaki et al. 2004; Kanzaki et al. 2006).

Surgical Methods

Surgically-assisted orthodontic tooth movement includes a broad range of invasive clinical procedures as an adjunct to orthodontic force application. The advantage of inducing a local surgical insult may at least in principle reduce some of the undesirable side effects of some pharmacological methods.

Dental Distraction

“Dental Distraction” was first described by Liou and Huang in 1998 as a means to accelerate orthodontic tooth movement. In a case series, the authors investigated the retraction of canines in patients who had first premolars extracted. Canine retraction was conducted by the surgical removal of inter-septal bone distal to the canine and the retraction was undertaken using a custom-made appliance. Canines moved 6-7mm in three weeks and the authors advocated the use of this method in maximal anchorage cases. Periodontal and bone healing was found to be uneventful (Liou and Huang 1998). Sayin et al. (2004) and Algayer et al. (2013) validated and advocated the use of this technique, reporting that dental distraction was a viable option which did not require additional surgical procedures, enabled reduced treatment time and decreased the need to supplement anchorage.

However, Kharkar et al. (2010) compared periodontal distraction (similar to the technique described by Liou and Huang as “dental distraction”) with dentoalveolar distraction (multiple holes connected medially, distally and apically; Figure 1). Clinical and radiographic means (periapical radiographs and lateral cephalograms) were used to assess the time required for retraction, canine tipping, anchorage loss and external root resorption. The dentoalveolar distraction group was found to be more effective with less root resorption. However, a major drawback of this study was that activation times of the distractor were different to that described by Liou and Huang (1998).

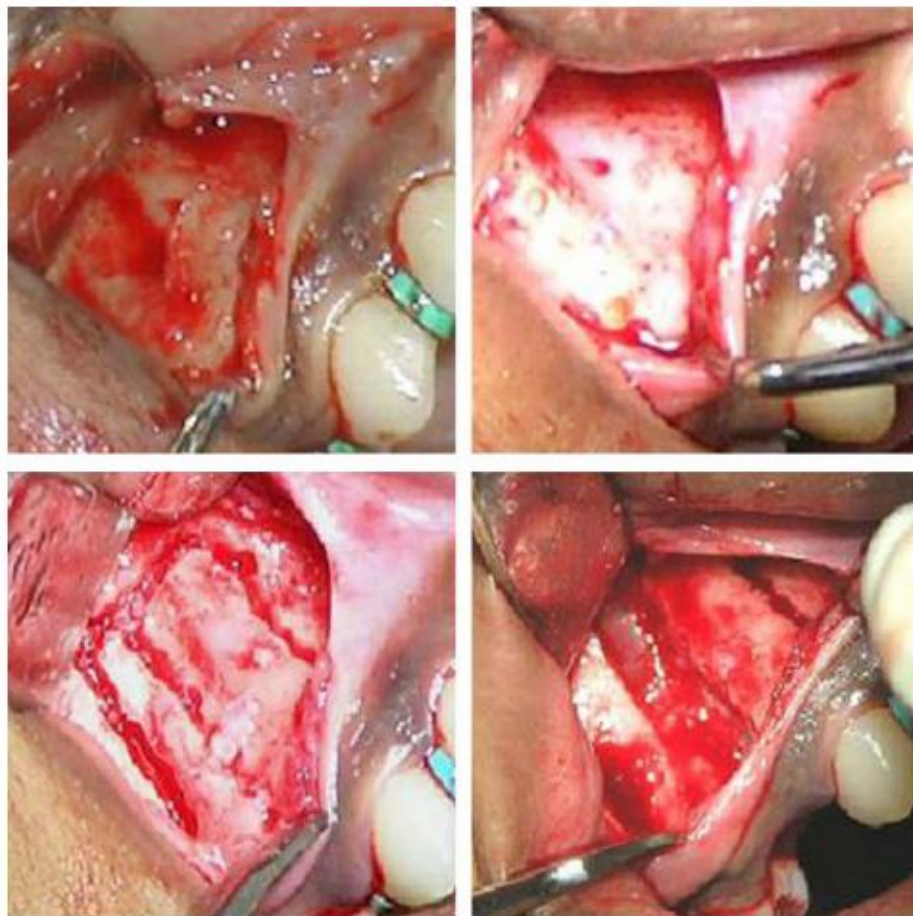


Figure 1. Technique for Dentoalveolar distraction (Kharkar, Kotrashetti et al. 2010)

Corticision

Corticision has been promoted as a minimally invasive alternative to create surgical injury to the bone without flap reflection. This surgical injury is believed to induce the regional acceleratory phenomena (RAP) and accelerate orthodontic tooth movement. This is performed

using a reinforced scalpel as a thin chisel to separate the interproximal cortices transmucosally, without raising a buccal or lingual soft tissue flap. Kim and colleagues (2009) investigated the effects of corticision on remodelling during orthodontic tooth movement. Three groups (orthodontic force only, orthodontic force with corticision and orthodontic force with corticision and periodic mobilisation) were assessed histologically and histomorphometrically at 7-day intervals for 28 days in a feline model. Corticision was found to promote catabolic and anabolic bone remodelling without any pathological changes or root resorption (assessed histologically). The investigation was unable to clarify the effect of periodic manipulation on the remodelling of bone and the rate of orthodontic tooth movement.

Piezocision

A more recent surgical method, piezocision has also been endorsed as a less invasive means of accelerating orthodontic tooth movement. Piezocision involves combining microincisions with selective tunnelling that allows for hard or soft tissue grafting and piezoelectric incisions (Dibart et al. 2011). In a case report, the authors used this technique in conjunction with the Invisalign appliance and found it to be effective and aesthetic (Keser and Dibart 2011). Advocates believe that piezocision allows for the rapid correction of severe malocclusions without the drawbacks of traumatic conventional corticotomy procedures (Sebaoun et al. 2011).

Corticotomy-Assisted Orthodontic Tooth Movement

Corticotomy assisted tooth movement is defined as a surgical procedure whereby the buccal and/or lingual cortical bone is cut, perforated or mechanically altered. This is performed without the involvement of the medullary bone, unlike osteotomies which involve the entire thickness of bone (Scheideman et al. 1985; Bogoch et al. 1993).

The earliest reports of corticotomy-enhanced tooth movement were described by George Cunningham in 1893. Cunningham presented a technique to the International Dental Congress in Chicago that incorporated mesial and distal interseptal osteotomies to facilitate repositioning of palatally-inclined maxillary teeth. Cunningham combined active surgical-

orthodontic techniques to reduce orthodontic treatment time in older patients (Cano et al. 2012).

A resurgence of corticotomy-enhanced tooth movement was initially driven by Heinrich Kole in 1959 with his publication of a series of articles on this topic. Kole described the surgical procedure as a “bony block” technique used to facilitate subsequent orthodontic treatment. He believed that orthodontic forces were resisted by the cortical bone and, therefore, cortical reduction by performing corticotomies would enable faster orthodontic tooth movement through the less dense medullary bone. Moreover, it was believed that by performing osteotomies on the cortical layer at different points, orthodontic treatment would be facilitated, preventing relapse with reduced orthodontic root resorption (Kole 1959a; Kole 1959b; Kole 1959c).

Suya (1991) published work on the use of corticotomy-assisted orthodontic treatment of 395 adult Japanese patients and found that some cases were completed in 6 months whilst others were completed in less than 12 months. Suyu believed this technique to be less painful, produced less root resorption and relapse in contrast to conventional orthodontics. He advocated that major tooth movements should be completed in 3-4 months as, after this, the edges of the bone blocks would fuse. He reported outstanding orthodontic results and patient satisfaction and concluded that only the sum total of all therapeutic “trauma” is significant; this philosophy was followed by the Wilco-Ferguson collaboration.

Wilkodontics

Most recently, the popularisation of corticotomy-assisted tooth movement arose from the case report publications of the Wilco brothers. A technique was described called Accelerated Osteogenic Orthodontics (AOO) which involved a combination of alveolar corticotomy with grafting (Wilco and Wilco 2001).

Wilco et al. subsequently described Periodontally Accelerated Osteogenic Orthodontics (PAOO), which is a combination of selective decortication and alveolar augmentation. It was believed that bone grafting of the cortical bones will allow for a greater scope of tooth movement and repair fenestrations and dehiscences, thus creating intact buccal and lingual plates of bone and enhance stability. Wilco et al. were also the first to propose that the rapid

tooth movement witnessed in AOO was not due to ‘bony block’ movement but rather was due to a transient localised remineralisation – demineralisation process occurring in the alveolar housing. This was consistent with the work of Frost (1983) who described this wound healing pattern as the regional acceleratory phenomenon (RAP) (Wilcko et al. 2008; Murphy et al. 2009; Wilcko et al. 2009; Wilcko and Wilcko 2013).

Regional Acceleratory Phenomena

Although the exact biological mechanism is poorly understood, it is believed that the increased tooth movement witnessed in corticotomy-assisted tooth movement is due to the regional acceleratory phenomenon (RAP) of wound healing. First coined by Orthopaedic surgeon Harold Frost in 1983, the RAP is a collection of physiological healing events with features including accelerated bone turnover and decreased bone density (Frost 1983).

In human autopsy material, Frost noted that in a resected sixth rib where thoracotomy had been previously undertaken, an increased bone turnover was evident by comparison with adjacent ribs. It was believed that the original injury accelerated the normal regional healing processes. The RAP did not provide new healing processes but increased the rapidity of the healing process (Figure 2). This may involve growth of skin, bone, cartilage and hair, turnover of bone, cartilage, synovial fluid, connective/fibrous tissue, chondral and bony modelling, skin epithelialisation, cicatrisation and cellular metabolism. Frost believed that any regional noxious stimuli could induce RAP. In humans, it is believed to begin within a few days of surgery with it being most pronounced at 1 to 2 months and taking from 6 to 24 months to dissipate. Frost stated that the duration and intensity of the RAP was proportional to the extent of injury and soft tissue involvement of the injury (Frost 1983; Frost 1989a; Frost 1989b).

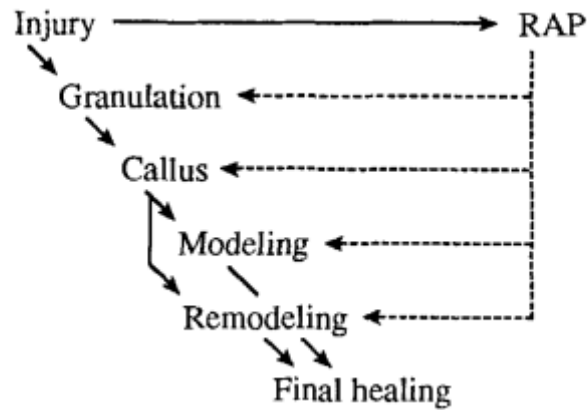


Figure 2: Acceleratory effects of RAP (Frost 1989)

Moreover a study on RAP in Wistar rats found that this phenomenon occurred as early as 10 days following bone injury and potentiated tissue healing; however, undesirable side effects such as dehiscences in periodontal surgery and open flap curettage might occur in areas where the bone is thin (Yaffe et al. 1994).

There is strong indirect evidence that the physiologic events associated with RAP following surgery may result in rapid tooth movement with corticotomy-facilitated tooth movement being three to four times faster than conventional orthodontic tooth movement. (Wilcko and Wilcko 2001). This effect was demonstrated in animal studies by Sebaoun et al., Teixeira et al. and Baloul et al. who separately found that increased orthodontic tooth movement was due to decreased bone volume, increased expression of inflammatory cytokines and increased osteoclast count and bone apposition width (Sebaoun et al. 2008; Teixeira et al. 2010; Baloul et al. 2011).

Systemic Effects

Mueller et al. (1991) investigated the impact of RAP on systemic bone metabolism in a rat model and found an increased mineralisation rate and formation. The authors created a burr hole in the left tibia and analysed both tibiae and femora and the fourth lumbar vertebra. After 7 days, femora, tibiae and fourth lumbar vertebrae showed a significant increase in mineral apposition rate, bone formation rate and mineralising surface. It was concluded that a systemic acceleratory phenomena accompanied the RAP.

Furthermore, an investigation by Schilling et al. (1998) found that a local RAP response was associated with increased systemic inflammatory markers, leading to a significant reduction of osteoblast number and bone volume.

The understanding of the systemic effects in a rat model was further elucidated by Verna et al. (1999) who conducted a histomorphometric study analysing the reaction of bone in rats undergoing orthodontic tooth movement. It was found that the RAP extended across the whole hemimaxilla, suggesting a systemic effect in this region.

From this information, the use of split mouth controls in the investigation of RAP, may not be suitable, due to the systemic acceleratory phenomenon.

Animal Research

Animal corticotomy research has been conducted in rats, dogs and cats (Iino et al. 2007; Lee et al. 2008; Sebaoun et al. 2008; Kim et al. 2009; Mostafa et al. 2009; Wang et al. 2009).

Duker (1975) was the first to experiment with corticotomy procedures using beagle dogs and concluded that neither periodontal attachment damage nor any significant pulpal injury occurred due to this procedure.

Iino et al. (2007) also investigated the effects of the corticotomy procedure in beagle dogs and suggested that the initial stages of orthodontic tooth movement were enhanced after the corticotomies were performed. This was thought to be due to a decrease in hyalinisation of the PDL at the compression side. The study compared the rate of tooth movement following a flap procedure alone with a corticotomy procedure and found a flap procedure by itself to be less effective

Cho et al. (2007) found an increase in the cellular activity of the formative and resorptive cells when protracting third premolars in beagle dogs. Mostafa et al. (2009) used dogs to explore corticotomy and orthodontic tooth movements and found that both groups followed the phases of orthodontic tooth movement of initial, lag and post-lag; however, the corticotomy group exhibited greater velocity.

Lee et al. (2008) used rats to compare corticotomy and osteotomy assisted tooth movement. They found that the osteotomy group displayed greater average tooth movement when compared with other groups (control and corticotomy) which showed no difference. Although the results were not statistically significant (due to high variation between the animals and breakages), neither the osteotomy nor control group showed the presence of a RAP, unlike the corticotomy group. The same sample was analysed histologically by Wang et al. (2009) and the results showed an up-regulation of osteoclasts in the corticotomy and tooth movement group versus the tooth movement only group in the first 21 days of the experiment.

Sebaoun et al. (2007) investigated the RAP response in rats undergoing corticotomy procedure. It was found that after three weeks, the surgical insult resulted in a significant increase in tissue turnover, which decreased by week 11. Of particular note (using H and E, and TRAP staining), they found less calcified spongiosa bone surface, greater periodontal ligament surface, higher osteoclast number and greater lamina dura apposition width in the group that experienced the surgical insult. Although the amount and type of trauma necessary to achieve the RAP was debatable, it was concluded that the degree was directly related to the intensity and proximity of surgical insult.

Baloul et al. (2011) also investigated the biological mechanisms behind corticotomy-enhanced orthodontic tooth movement using 114 Sprague-Dawley rats. The animals were divided into selective alveolar decortication alone, tooth movement alone and “combined” therapy (selective alveolar decortication alone and tooth movement), with the left first maxillary molar used as the experimental tooth. Measurements were performed at baseline (day 0: no treatment rendered) and on days 3, 7, 14, 21, 28 and 42.

By utilising radiographic, tomographic and molecular methods, Baloul et al. (2011) found alveolar decortication enhanced the initial rate of tooth movement due to changes in the mechanism of bone resorption and bone formation during the earlier stages of treatment. In particular, the combined group showed significantly decreased bone volume and mineral content, as well as increased tooth movement, when compared with the tooth movement alone group. Increased cell numbers associated with osteoclastic activity (M-CSF [macrophage colony stimulating factor], RANKL [receptor activator of nuclear factor kappa-

β ligand], OPG [osteoprotegerin], calcitonin receptor [CTR], TRACP-5b [tartrate-resistant acid phosphatase 5b], cathepsin K [Ctsk]), and osteoblastic activity (OPN [osteopontin], BSP [bone sialoprotein], OCN [osteocalcin]) were found.

Human Research

The current literature is predominantly in the form of case reports with the combination of corticotomies accompanying a variety of orthodontic treatment modalities; including, molar intrusion (Hwang and Lee 2001; Moon et al. 2007; Oliveira et al. 2008), retraction of anterior teeth in bimaxillary protrusion cases (Iino et al. 2006), traction of impacted canines (Fischer 2007), treatment of ankylosed teeth (Hwang et al. 2011), closure of anterior open bite (Generson et al. 1978; Kanno et al. 2007; Akay et al. 2009) and the correction of transverse discrepancies (Mossaz et al. 1992).

Wilcko et al. concluded that AOO/PAOO could be used to treat moderate to severe malocclusions in adolescents and adults. When compared with conventional treatment, it was believed that a reduction in the need for extractions and orthodontic side effects (such as root resorption, relapse, inadequate basal bone and bacterial time/load factors) resulted (Wilcko and Wilcko 2001; Wilcko et al. 2008; Murphy et al. 2009; Wilcko et al. 2009; Wilcko and Wilcko 2013).

Aboul-ela et al. (2011) reported that gingival index scores increased in their experimental corticotomy group; however, this may be part of gingival healing and overall no statistically significant difference between preoperative and postoperative measurements of plaque index, probing depth, attachment loss and gingival recession were found between corticotomy versus non-corticotomy side. Long et al. (2012), in a systematic review, reported that corticotomy is a relatively safe and effective intervention.

Conversely, many authors have also had reservations regarding the use of corticotomy assisted tooth movement. Reichenbach (1965) believed periodontal pocket formation and alveolar necrosis could occur due to this procedure (Cano et al. 2012). Bell and Levy (1972) believed that corticotomies caused a 'destructive effect'. Furthermore, authors such as

Merrill and Pedersen believed that little time was saved when using corticotomy assisted tooth movement. However, more recent literature has aided understanding.

Cassetta et al. (2012), in a study on the impact of corticotomy assisted orthodontic treatment on oral health-related quality of life, found that regardless of the surgical intervention (osteotomy cuts, piezoelectric surgery or conventional rotatory osteotomy), subjects showed increased Oral Health Impact Profile (OHIP-14) scores which meant they experienced functional limitations, physical disability and handicap.

Prospective Trials

Three studies are particularly noteworthy, as they are prospective trials. Fischer (2007) treated six consecutive patients presenting with bilaterally impacted canines. A split mouth study was undertaken with one canine exposed using a conventional surgical procedure whilst the contralateral canine was exposed using a corticotomy-assisted technique (series of circular holes were made along the bone mesial and distal adjacent to the impacted tooth). Tooth movement of both canines was performed using 60g of force and comparisons were undertaken. A reduction of treatment time was found in the corticotomy-assisted canine group (28-33% reduction) with no significant differences in clinical or radiographic assessment of the periodontium.

The second study of interest is that of Lee et al. (2007) who investigated the treatment outcomes in 65 female patients in three different groups; orthodontic treatment alone, corticotomy-assisted orthodontic treatment and anterior segmental osteotomy in the maxilla and mandible. Cephalometric measurements were used to evaluate the treatment outcomes. The authors recommended that orthodontic treatment alone, or corticotomy-assisted orthodontic treatment was able to produce reduction in severe incisor proclination with normal basal bone position, with the corticotomy group being able to do this with greater efficiency and effectiveness, compared with the orthodontic treatment alone group. However, the anterior segmental osteotomy showed the largest amount of basal bone retraction and the least amount of upper incisor inclination change and upper alveolar bone bending of the three groups.

The third study is that of Aboul-Ela et al. (2011) who investigated the retraction of mini-screw supported maxillary canines with and without corticotomy-facilitated orthodontics in thirteen Class II div I adult patients with increased overjet. A split mouth design was undertaken with corticotomy-facilitated orthodontics randomly assigned to one side of the maxillary arch at the canine-premolar region and the other side served as the control. The investigators found that the average daily rate of canine retraction was significantly higher on the corticotomy side. This was twice as great in the first 2 months after the corticotomy surgery with a steady decline to 1.6 times greater in the third month and 1.06 times greater by the end of the fourth month. No statistically significant difference in molar anchorage, plaque index, probing depth, attachment loss or gingival recession were noted between the groups.

Flap only

Several authors have suggested that flap surgery alone would be sufficient to induce RAP and assist with orthodontic tooth movement (Yaffe et al. 1994; Binderman et al. 2001).

Binderman et al. (2001) used a rat model to determine if dissection of the papilla and dentogingival and dento-periosteal fibres, (coronal approach versus an apical approach) is necessary to induce a biological response. The authors found that the coronal approach caused an extensive resorptive phase in the PDL surface of the alveolar bone with increased osteoclasts, empty osteocyte lacunae and occlusion of blood vessels. By contrast, the apical approach group had only slight resorption of the outer aspect of bone with some apposition of bone at the alveolar crest was evident. The results showed that periodontal surgery, by a coronal surgical approach, was more effective. The authors also concluded that the elevation of the mucoperiosteum was not responsible for alveolar bone loss (Binderman et al. 2001).

Furthermore, Binderman et al. (2010) believed that the detachment of dentogingival and interdental fibres would be sufficient to upregulate osteoclastogenesis and resorb alveolar bone. The authors considered that, although a corticotomy would increase bone resorption, this was largely unnecessary as fiberotomy alone would suffice.

The work of Binderman et al. (2010) supported the earlier works Yaffe et al. who, using a rat model, assessed the influence of a mucoperiosteal flap on the initiation of the RAP at days 3, 7, 10, 14, 21 and 120 days. The authors found that the RAP occurred as early as 10 days, with increased bone resorption and more so if the flap was performed on the buccal and lingual aspects. The RAP was undetectable at 120 days (Yaffe et al. 1994).

However, doubt has been cast on these findings by authors such as Iino et al. (2007) who believe that bony surgical intervention is required to elicit a sufficient RAP to promote tooth movement. These authors found a statistically significant increased the rate of tooth movement in the corticotomy group, compared with the flap-only group. This was supported by Sebaoun et al. (2008) who found greater osteoclast cell counts around the experimental tooth, as compared with the contralateral tooth. In a case series by Fischer (2007), greater tooth movement was observed in the orthodontic traction of impacted canines, when comparing a corticotomy with surgical flap.

Orthodontically Induced Inflammatory Root Resorption

First described by Bates in 1856, Orthodontically Induced Inflammatory Root Resorption (OIIRR) is a relatively common, unwelcome outcome of orthodontic treatment. It is a pathological process which involves the destruction of formed tissue with the active removal of mineralised cementum and dentine (Brudvik and Rygh 1994). It is believed to be the result of a combination of individual biological variability and the effect of mechanical stimulus (Killiany 1999).

Although difficult to avoid this negative sequela of treatment, histological studies in the literature identify a greater than 90% occurrence. However, the premature loss of tooth or teeth, due to root resorption, is relatively uncommon (Stenvik 1970; Harry and Sims 1982; Killiany 1999; Harris 2000).

The extent of root structure involvement can allow for a broad classification of OIIRR.

1. Surface resorption: Involves only the outer cemental layers and, once the stimulus is removed, the tooth structure is able to be fully regenerated.

2. Deep resorption: Involves the cementum and outer dentine layers, since this is generally repaired with cementum, the morphology of the root may or may not mimic that of the original.
3. Circumferential apical root resorption: This involves the tridimensional resorption of cementum and dentine of the root apex. Since regeneration is not possible, the result is root shortening (Brezniak and Wasserstein 2002).

OIIRR can be described in two distinct phases. The first involves injury to the external surface of the root, exposing denuded mineralised tissue and extended stimulation of multinucleated giant cells which start the resorption process. The second phase represents repair, in which the tooth root repairs with cementum-like material within 2-3 weeks once the stimulation ceases (Trope 2002).

Cellular Processes

Most notably, the work by Brudvik and Rygh on rodents, confirmed the cellular processes which occur during OIIRR. As teeth are moved within bone, areas of pressure in the periodontal ligament cause sterile ischaemic necrosis in zones of hyalinisation. Cells negative for tartrate-resistant acid phosphatase (TRAP) act as macrophage-like cells which remove the necrotic tissue. This process is initially confined to the periphery of the hyaline zone; however, the outer layer of the root can also be damaged during this process (cementoblast layer). This causes denudation of the root surface which allows orthodontic force to directly damage the root and necrosis of the tissue which is subsequently removed by scavenger cells. Continued force causes larger areas of damage leading to odontoclast activation and dentine resorption (Brudvik and Rygh 1993; Brudvik and Rygh 1994a; Brudvik and Rygh 1994b).

The resorption process ceases once all hyaline tissue is removed and/or force levels decrease. This allows for repair of the root structure to begin and progressive remodelling to occur. Infilling of resorption lacunae with secondary cementum (acellular and cellular) occurs either from the periphery or centre of the resorption cavity (Brudvik and Rygh 1994a; Brudvik and Rygh 1994b; Owman-Moll and Kurol 1998; Brezniak and Wasserstein 2002; Trope 2002). This process is believed to be initiated once the orthodontic force is below 20-26 g/cm² (Schwarz 1932).

Classification and detection

The detection of OIIRR in clinical orthodontics is most commonly undertaken by radiographic means. However, the loss of root structure can only be detected when increased loss of root structure (dentine) occurs. Commonly, this takes 3-5 months of orthodontic force application (Fuss et al. 2003).

In a study by Lim et al. (2012), operators in Australia and The United States of America commonly approached the diagnosis and management of root resorption by:

- (1) Screening patients using an orthopantomogram and undertaking additional periapical radiographs for 'higher risk' patients, particularly individuals with a history of root resorption;
- (2) 6-monthly radiographic review during treatment;
- (3) The use of light and/or discontinuous forces every 2-3 months;
- (4) The extraction of deciduous teeth if permanent successors were erupting ectopically and causing damage to adjacent root structures; and
- (5) The use of fixed retention after treatment.

In a study by Sameshima and Sinclair (2001), 868 orthodontically-treated patients were assessed for root resorption via periapical films. It was found that the most significant resorption occurred in the maxillary lateral incisors, in teeth with abnormal root morphology (pipette, pointed or dilacerated) and in patients with increased overjet. Adult patients experienced more resorption than children in the mandibular anterior segment only and racial variations were evident with Asian patients experiencing significantly less root resorption than white or Hispanic patients.

Diagnosis

In orthodontic research, the detection of OIIRR has been undertaken primarily by radiographs, histological means (light microscopy and scanning electron microscopy), and microcomputed tomography (micro-CT).

Common problems using plain film radiographs is the overestimation of OIIRR using periapical films and underestimation using panoramic films (Sameshima and Sinclair 2001; Dudic et al. 2008; Dudic et al. 2009). Although, when compared with panoramic imaging, periapical imaging results in less image magnification and distortion and thus provides greater accuracy (Taylor and Jones 1995). Chan and Darendeliler (Chan and Darendeliler 2005) concluded that plain film radiographs are important in detecting OIIRR; however, quantitative measurements are relatively inaccurate and, therefore, should be avoided. The authors concluded that 3D volumetric radiography demonstrated a feasible, accurate and repeatable alternative in measuring OIIRR (Chan and Darendeliler 2005). These findings have been supported by other authors (Bjerklin and Ericson 2006; Alqerban et al. 2009; Ponder et al. 2013).

Microcomputed Tomography

Feldkamp et al. (1989) pioneered Microcomputed Tomography (micro-CT) which is an x-ray imaging technology used to visualise mineralised tissues in three dimensions at high resolution. It is capable of volumetric CT analysis with isotropic voxel spacing of <math><100\ \mu\text{m}</math> (Feldkamp et al. 1989; Holdsworth and Thornton 2002). It is frequently utilised when assessing tooth movement in an animal model; however, due to its small gantry it can only be used in ex-vivo human dental material (Harris et al. 1997; Wierzbicki et al. 2009). The use of micro-CT in small animal research has included the study of bone, phenotype evaluation and vascular imaging (Holdsworth and Thornton 2002). Of particular interest, it has been used to study root resorption in ex-vivo human and animal models (Harris et al. 2006; Chung et al. 2008; Furfaro et al. 2014).

The advantages of its use include the ability to provide qualitative and quantitative results in 3D morphology; it does not interfere with anatomical tissue and has the ability of making time-dependant comparisons (before and after sacrifice). However, limitations include soft-tissue contrast, which is inherently poor with X-ray CT, artefacts need to be digitally compensated for and the use of ionizing radiation results in potential risks to research animals (especially in longitudinal animal studies) (Holdsworth and Thornton 2002).

The Animal Model

Experimental studies on animals can be broadly divided into basic biological research in which the aim is to gain a greater understanding of biological processes and studies which gather clinical information from the use of new treatment modalities (Reitan and Kvam 1971). In orthodontics, common animal models include mice, rats, guinea pigs, rabbits, cats, dogs and monkeys.

Fundamental genetic and anatomical differences between these models and humans mean the model validity requires thought and deliberation. In particular, the conclusions that can be drawn from the experimental findings must be carefully assessed (Reitan and Kvam 1971).

Although monkeys are the closest, genetically and anatomically, to humans, distinct morphological differences are still present (larger interproximal and interradicular marrow spaces and fewer and relatively smaller alveolar crest marrow spaces) and increased cost (compared with other animal models) is often prohibitive. It is important to note that dogs and monkeys have greater morphological similarity of teeth and supporting structures to human teeth than rats (Macapanpan et al. 1954; Reitan and Kvam 1971).

Ren et al. (2004), in a systematic review, found that 55% of the 320 animal investigations included in their study were undertaken in rats. Rats have several advantages over other animals. The main advantages being that they are relatively inexpensive and accessible, easier to handle and prepare histologically, antibodies required for immunological surveys are easier to obtain, they have an omnivorous diet, short time space of generations, large litters and ease of standardisation.

Although the use of rats is advantageous over mice when appliances require construction (as mice are too small), the rat molar is still significantly smaller in size (being approximately 50 times smaller than a human molar) and, therefore, it can still be difficult to fabricate appliances (Macapanpan et al. 1954; Ren et al. 2004).

Considerations must be given to distinctive features in the rat model as they can influence the experimental design and results. Distinct morphological difference exists within the alveolar bone which has greater density and fewer marrow spaces and often presents as aplastic or

undergoing bone resorption (Reitan and Kvam 1971; Ren et al. 2004). Kindlova and Sheinin (1968) found that the vascular supply of the interdental papilla of the rat is anatomically different from that of the human. Hyalinisation occurs relatively rapidly and can be present as early as six hours after force delivery (Macapanpan et al. 1954).

Rat molars also undergo natural distal drift and continuous eruption of the incisors. This is due to continuous bony remodelling and, in particular, bone formation on the mesial side and active resorption on the distal side can lead to physiological root resorption (Reitan and Kvam 1971; Roberts and Morey 1985; Kimura et al. 2003; Foo et al. 2007). Kimura et al. (2003) using electron microscopy, showed that this peaks at 5-6 weeks of age.

Ren et al. (2004) stated that when investigating tooth movements in a rat model, mesial molar movement is most favourable, as the buccal side has a limited amount of bone which is more compact. Ideally, the force level in a rat model should not exceed 20cN when mesial movement is planned because it is equivalent to a force of 1000cN (1kg) applied to a human molar. However, due to a lack of trabecular bone, buccal tooth movement may require a heavier force application (Ren, Maltha et al. 2004).

Rat models can provide useful information in studies which evaluate orthodontic tooth movement, especially since a biological response at the linear phase of tooth movement can be achieved with a minimum experimental period of two weeks. Despite orthodontic tooth movement being significantly faster in rats than humans, the principal mechanisms of tooth movement in rats are similar to humans with initial tooth movement being faster in juvenile than adult rats (Ren, Maltha et al. 2004).

A lack of current knowledge regarding the biological response of corticotomy-assisted tooth movement, in particular the response of the tooth root, supports the need for further investigation in this field. A rat provides a reliable and efficient model for orthodontic research.

References

- Aboul-Ela, S. M. B. E.-D., A. R. El-Beialy, et al. (2011). "Miniscrew implant-supported maxillary canine retraction with and without corticotomy-facilitated orthodontics." American Journal of Orthodontics and Dentofacial Orthopedics **139**(2): 252-259.
- Akay, M. C., A. Aras, et al. (2009). "Enhanced effect of combined treatment with corticotomy and skeletal anchorage in open bite correction." Journal of Oral and Maxillofacial Surgery **67**(3): 563-569.
- Al-Sayagh, N. M. and D. K. A. Salman (2014). "The Effect of Mechanical Vibration on the velocity of Orthodontic tooth Movement." International Journal of Enhanced Research in Science Technology and Engineering **3**(1): 284-291.
- Allgayer, S., G. Rosenbach, et al. (2013). "Periodontal ligament distraction: esthetics and occlusal stability at the 2-year follow-up." American Journal of Orthodontics and Dentofacial Orthopedics **143**(4): 535-546.
- Algerban, A., R. Jacobs, et al. (2009). "In-vitro comparison of 2 cone-beam computed tomography systems and panoramic imaging for detecting simulated canine impaction-induced external root resorption in maxillary lateral incisors." American Journal of Orthodontics and Dentofacial Orthopedics **136**(6): 764. e761-764. e711.
- Baloul, S. S., L. C. Gerstenfeld, et al. (2011). "Mechanism of action and morphologic changes in the alveolar bone in response to selective alveolar decortication-facilitated tooth movement." American Journal of Orthodontics and Dentofacial Orthopedics **139**(4): S83-S101.
- Baumrind, S. (1969). "A reconsideration of the propriety of the "pressure-tension" hypothesis." American Journal of Orthodontics **55**(1): 12-22.
- Baumrind, S. and D. L. Buck (1970). "Rate changes in cell replication and protein synthesis in the periodontal ligament incident to tooth movement." American Journal of Orthodontics **57**(2): 109-131.
- Becker, R. O., C. Bassett, et al. (1964). "Bioelectric factors controlling bone structure." H. Frost. New York: Little Brown.
- Bell, W. H. and B. M. Levy (1972). "Revascularization and bone healing after maxillary corticotomies." Journal of Oral Surgery (American Dental Association: 1965) **30**(9): 640-648.
- Binderman, I., M. Adut, et al. (2001). "Alveolar bone resorption following coronal versus apical approach in a mucoperiosteal flap surgery procedure in the rat mandible." Journal of Periodontology **72**(10): 1348-1353.
- Binderman, I., N. Gadban, et al. (2010). "Commentary on: periodontally accelerated osteogenic orthodontics (PAOO)—a clinical dilemma." International Orthodontics **8**(3): 268-277.
- Bjerklin, K. and S. Ericson (2006). "How a computerized tomography examination changed the treatment plans of 80 children with retained and ectopically positioned maxillary canines." Angle Orthodontist **76**(1): 43-51.
- Bogoch, E., N. Gschwend, et al. (1993). "Healing of cancellous bone osteotomy in rabbits—Part I: Regulation of bone volume and the regional acceleratory phenomenon in normal bone." Journal of Orthopaedic Research **11**(2): 285-291.
- Bosshardt, D. D. and K. A. Selvig (1997). "Dental cementum: the dynamic tissue covering of the root." Periodontology 2000 **13**(1): 41-75.
- Bosshardt, D. (2005). "Are cementoblasts a subpopulation of osteoblasts or a unique phenotype?" Journal of Dental Research **84**(5): 390-406.

- Brezniak, N. and A. Wasserstein (2002). "Orthodontically induced inflammatory root resorption. Part I: the basic science aspects." Angle Orthodontist **72**(2): 175-179.
- Brudvik, P. and P. Rygh (1993). "The initial phase of orthodontic root resorption incident to local compression of the periodontal ligament." The European Journal of Orthodontics **15**(4): 249-263.
- Brudvik, P. and P. Rygh (1994a). "Root resorption beneath the main hyalinized zone." The European Journal of Orthodontics **16**(4): 249-263.
- Brudvik, P. and P. Rygh (1994b). "Multi-nucleated cells remove the main hyalinized tissue and start resorption of adjacent root surfaces." The European Journal of Orthodontics **16**(4): 265-273.
- Burstone, C. J. (1962). "The biomechanics of tooth movement." Vistas in orthodontics, Lea and Febiger, Philadelphia: 197-213.
- Cano, J., J. Campo, et al. (2012). "Corticotomy-assisted orthodontics." Journal of Clinical and Experimental Dentistry **4**(1): 54-59.
- Cassetta, M., S. Di Carlo, et al. (2012). "The impact of osteotomy technique for corticotomy-assisted orthodontic treatment (CAOT) on oral health-related quality of life." European Review for Medical Pharmacological Sciences **16**(12): 1735-1740.
- Chan, E. and M. A. Darendeliler (2005). "Physical properties of root cementum: Part 5. Volumetric analysis of root resorption craters after application of light and heavy orthodontic forces." American Journal of Orthodontics and Dentofacial Orthopedics **127**(2): 186-195.
- Cho, K. W., S. W. Cho, et al. (2007). "The effect of cortical activation on orthodontic tooth movement." Oral Diseases **13**: 314-319.
- Chung, C. J., K. Soma, et al. (2008). "OPN deficiency suppresses appearance of odontoclastic cells and resorption of the tooth root induced by experimental force application." Journal of Cellular Physiology **214**(3): 614-620.
- Collins, M. K. and P. M. Sinclair (1988). "The local use of vitamin D to increase the rate of orthodontic tooth movement." American Journal of Orthodontics and Dentofacial Orthopedics **94**(4): 278-284.
- Cruz D., E. Kohara, et al. (2004). "Effects of low-intensity laser therapy on the orthodontic movement velocity of human teeth: a preliminary study." Lasers in Surgery and Medicine **35**(2):117-20.
- Darendeliler, M. A., P. M. Sinclair, et al. (1995). "The effects of samarium-cobalt magnets and pulsed electromagnetic fields on tooth movement." American Journal of Orthodontics and Dentofacial Orthopedics **107**(6): 578.
- Darendeliler, M., A. Darendeliler, et al. (1997). "Effects of static magnetic and pulsed electromagnetic fields on bone healing." The International Journal of Adult Orthodontics and Orthognathic Surgery **12**(1): 43.
- Darendeliler, M. A., A. Zea, et al. (2007). "Effects of pulsed electromagnetic field vibration on tooth movement induced by magnetic and mechanical forces: a preliminary study." Australian Dental Journal **52**(4): 282-287.
- Davidovitch, Z., M. D. Finkelson, et al. (1980). "Electric currents, bone remodeling, and orthodontic tooth movement: II. Increase in rate of tooth movement and periodontal cyclic nucleotide levels by combined force and electric current." American Journal of Orthodontics **77**(1): 33-47.
- Dibart, S., J. D. Sebaoun, et al. (2009). "Piezocision: Minimally Invasive Periodontally Accelerated Orthodontic Tooth Movement Procedure." Compendium of Continuing Education in Dentistry **30**: 342-344.
- Dudic, A., C. Giannopoulou, et al. (2009). "Detection of apical root resorption after orthodontic treatment by using panoramic radiography and cone-beam computed

- tomography of super-high resolution." American Journal of Orthodontics and Dentofacial Orthopedics **135**(4): 434-437.
- Dudic, A., C. Giannopoulou, et al. (2008). "Diagnostic accuracy of digitized periapical radiographs validated against micro-computed tomography scanning in evaluating orthodontically induced apical root resorption." European Journal of Oral Sciences **116**(5): 467-472.
- Düker, J. (1975). "Experimental animal research into segmental alveolar movement after corticotomy." Journal of Maxillofacial Surgery **3**: 81-84.
- Feldkamp, L. A., S. A. Goldstein, et al. (1989). "The direct examination of three-dimensional bone architecture in vitro by computed tomography." Journal of Bone and Mineral Research **4**(1): 3-11.
- Fischer, T. (2007). "Orthodontic treatment acceleration with corticotomy-assisted exposure of palatally impacted canines: a preliminary study." Angle Orthodontist **77**(3): 417-420.
- Foo, M., A. Jones, et al. (2007). "Physical properties of root cementum: part 9. Effect of systemic fluoride intake on root resorption in rats." American Journal of Orthodontics and Dentofacial Orthopedics **131**(1): 34-43.
- Frost, H. M. (1983). "The regional acceleratory phenomenon: a review." Henry Ford Hospital Medical Journal **31**(1): 3-9.
- Frost, H. (1989a). "The biology of fracture healing: an overview for clinicians. Part I." Clin Orthop Relat Res **248**: 283-293.
- Frost, H. (1989b). "The biology of fracture healing: an overview for clinicians. Part II." Clinical Orthopaedics and Related Research **248**: 294-309.
- Frost, H. M. (1994). "Wolff's Law and bone's structural adaptations to mechanical usage: an overview for clinicians." Angle Orthodontist **64**(3): 175-188.
- Fukada, E. and I. Yasuda (1957). "On the piezoelectric effect of bone." Journal of the Physical Society of Japan **12**(1158): 139-155.
- Furfaro, F., E. S. Ang, et al. (2014). "A histological and micro-CT investigation in to the effect of NGF and EGF on the periodontal, alveolar bone, root and pulpal healing of replanted molars in a rat model-a pilot study." Progress in Orthodontics **15**(1): 2.
- Fuss, Z., I. Tsesis, et al. (2003). "Root resorption- diagnosis, classification and treatment choices based on stimulation factors." Dental Traumatology **19**(4): 175-182.
- Generson, R., J. Porter, et al. (1978). "Combined surgical and orthodontic management of anterior open bite using corticotomy." Journal of Oral Surgery (American Dental Association: 1965) **36**(3): 216-219.
- Gianelly, A. A. (1969). "Force-induced changes in the vascularity of the periodontal ligament." American Journal of Orthodontics **55**(1): 5-11.
- Gilsanz, V., T. A. Wren, et al. (2006). "Low-level, high-frequency mechanical signals enhance musculoskeletal development of young women with low BMD." Journal of Bone and Mineral Research **21**(9): 1464-1474.
- Gottlieb, B. (1946). "Some orthodontic problems in histologic illumination." American Journal of Orthodontics and Oral Surgery **32**(3): 113-133.
- Graber, T. (1976). "An orthodontic perspective after 75 years." American Journal of Orthodontics **69**(5): 572-583.
- Graber, L. W., R. L. Vanarsdall Jr, et al. (2011). Orthodontics: current principles and techniques, Elsevier Health Sciences.
- Grimm, F. M. (1972). "Bone bending, a feature of orthodontic tooth movement." American Journal of Orthodontics **62**(4): 384-393.
- Harris, D. A., A. S. Jones, et al. (2006). "Physical properties of root cementum: part 8. Volumetric analysis of root resorption craters after application of controlled intrusive

- light and heavy orthodontic forces: a microcomputed tomography scan study." American Journal of Orthodontics and Dentofacial Orthopedics **130**(5): 639-647.
- Harris, E. F., S. E. Kineret, et al. (1997). "A heritable component for external apical root resorption in patients treated orthodontically." American Journal of Orthodontics and Dentofacial Orthopedics **111**(3): 301-309.
- Harris, E. F. (2000). "Root resorption during orthodontic therapy." Seminars in Orthodontics **6**(3): 183-194.
- Harry, M. and M. Sims (1982). "Root resorption in bicuspid intrusion: a scanning electron microscope study." Angle Orthodontist **52**(3): 235-258.
- Hashimoto, F., Y. Kobayashi, et al. (2001). "Administration of osteocalcin accelerates orthodontic tooth movement induced by a closed coil spring in rats." The European Journal of Orthodontics **23**(5): 535-545.
- Heller, I. J. and R. Nanda (1979). "Effect of metabolic alteration of periodontal fibers on orthodontic tooth movement: an experimental study." American Journal of Orthodontics **75**(3): 239-258.
- Holdsworth, D. W. and M. M. Thornton (2002). "Micro-CT in small animal and specimen imaging." Trends in Biotechnology **20**(8): S34-S39.
- Hwang, H.-S. and K.-H. Lee (2001). "Intrusion of overerupted molars by corticotomy and magnets." American Journal of Orthodontics and Dentofacial Orthopedics **120**(2): 209-216.
- Hwang, D.-H., K.-H. Park, et al. (2011). "Treatment of Class II open bite complicated by an ankylosed maxillary central incisor." Angle Orthodontist **81**(4): 726-735.
- Iglesias-Linares, A., A. Moreno-Fernandez, et al. (2011). "The use of gene therapy vs. corticotomy surgery in accelerating orthodontic tooth movement." Orthodontic and Craniofacial Research **14**(3): 138-148.
- Iino, S., S. Sakoda, et al. (2006). "An adult bimaxillary protrusion treated with corticotomy-facilitated orthodontics and titanium miniplates." Angle Orthodontist **76**(6): 1074-1082.
- Iino, S., S. Sakoda, et al. (2007). "Acceleration of orthodontic tooth movement by alveolar corticotomy in the dog." American Journal of Orthodontics and Dentofacial Orthopedics **131**(4): 448.e441-448.e448.
- Julien, K. C., P. H. Buschang, et al. (2013). "Prevalence of white spot lesion formation during orthodontic treatment." Angle Orthodontist **83**(4): 641-647.
- Kanno, T., M. Mitsugi, et al. (2007). "Corticotomy and compression osteogenesis in the posterior maxilla for treating severe anterior open bite." International Journal of Oral and Maxillofacial Surgery **36**(4): 354-357.
- Kanzaki, H., M. Chiba, et al. (2004). "Local OPG gene transfer to periodontal tissue inhibits orthodontic tooth movement." Journal of Dental Research **83**(12): 920-925.
- Kanzaki, H., M. Chiba, et al. (2006). "Local RANKL gene transfer to the periodontal tissue accelerates orthodontic tooth movement." Gene Therapy **13**(8): 678-685.
- Keser, E. I. and S. Dibart (2011). "Piezocision-assisted Invisalign treatment." Compendium of Continuing Education in Dentistry **32**(2): 46-48, 50-41.
- Kharkar, V., S. Kotrashetti, et al. (2010). "Comparative evaluation of dento-alveolar distraction and periodontal distraction assisted rapid retraction of the maxillary canine: a pilot study." International Journal of Oral and Maxillofacial Surgery **39**(11): 1074-1079.
- Killiany, D. M. (1999). "Root resorption caused by orthodontic treatment: An evidence-based review of literature." Seminars in Orthodontics **5**(2):128-133.
- Kim, S.-J., Y.-G. Park, et al. (2009). "Effects of Corticision on paradental remodeling in orthodontic tooth movement." Angle Orthodontist **79**(2): 284-291.

- Kimura, R., H. Anan, et al. (2003). "Dental root resorption and repair: histology and histometry during physiological drift of rat molars." Journal of Periodontal Research **38**(5): 525-532.
- Kindlová, M. and A. Scheinin (1968). "The Vascular Supply of the Gingiva and the Alveolar Mucosa in the Rat: I. Description of the Method and the Morphology." Acta Odontologica Scandinavica **26**(6): 617-628.
- Kobayashi, Y., H. Takagi, et al. (1998). "Effects of local administration of osteocalcin on experimental tooth movement." Angle Orthodontist **68**(3): 259-266.
- Kohno, T., Y. Matsumoto, et al. (2002). "Experimental tooth movement under light orthodontic forces: rates of tooth movement and changes of the periodontium." Journal of Orthodontics **29**(2): 129-136.
- Kole, H. (1959a). "Surgical operations on the alveolar ridge to correct occlusal abnormalities. Part 1." Oral Surgery, Oral Medicine, Oral Pathology **12**(5): 277-288.
- Kole, H. (1959b). "Surgical operations on the alveolar ridge to correct occlusal abnormalities. Part 2." Oral Surgery, Oral Medicine, Oral Pathology **12**(5): 413-420.
- Kole, H. (1959c). "Surgical operations on the alveolar ridge to correct occlusal abnormalities. Part 3." Oral Surgery, Oral Medicine, Oral Pathology **12**(5): 515-529.
- Krishnan, V. and Z. e. Davidovitch (2006). "Cellular, molecular, and tissue-level reactions to orthodontic force." American Journal of Orthodontics and Dentofacial Orthopedics **129**(4): 469. e461-469. e432.
- Kua, C. H., A. Kantarci, et al. (2013). "Photobiomodulation accelerates orthodontic alignment in the early phase of treatment." Progress in Orthodontics **14**(30):1-9.
- Kvam, E. (1968). "A study of the cell-free zone following experimental tooth movement in the rat. " Report of the congress. European Orthodontic Society.
- Lee, J.-K., K.-R. Chung, et al. (2007). "Treatment outcomes of orthodontic treatment, corticotomy-assisted orthodontic treatment, and anterior segmental osteotomy for bimaxillary dentoalveolar protrusion." Plastic and Reconstructive Surgery **120**(4): 1027-1036.
- Lee, W., G. Karapetyan, et al. (2008). "Corticotomy-/osteotomy-assisted tooth movement microCTs differ." Journal of Dental Research **87**(9): 861-867.
- Lee, W., G. Karapetyan, et al. (2008). "Corticotomy-/osteotomy-assisted tooth movement microCTs differ." Journal of Dental Research **87**(9): 861-867.
- Lim, E., G. Sameshima, et al. (2012). "Comparison of Australian and American orthodontic clinical approaches towards root resorption." Australian Orthodontic Journal **28**(2): 181.
- Lindhe, J., N. P. Lang, et al. (2009). Clinical periodontology and implant dentistry, John Wiley and Sons.
- Liou, E. J. and C. S. Huang (1998). "Rapid canine retraction through distraction of the periodontal ligament." American Journal of Orthodontics and Dentofacial Orthopedics **114**(4): 372-382.
- Long, H., U. Pyakurel, et al. (2012). "Interventions for accelerating orthodontic tooth movement: a systematic review." Angle Orthodontist **83**(1): 164-171.
- Macapanpan, L. G., J. P. Weinmann, et al. (1954). "Early Tissue Changes Following Tooth Movement In Rats*." Angle Orthodontist **24**(2): 79-95.
- McDonald, F. (1993). "Electrical effects at the bone surface." The European Journal of Orthodontics **15**(3): 175-183.
- Meghji, S. (1992). "Bone remodelling." British Dental Journal **172**(6): 235-242.
- Meikle, M. C. (2006). "The tissue, cellular, and molecular regulation of orthodontic tooth movement: 100 years after Carl Sandstedt." The European Journal of Orthodontics **28**(3): 221-240.

- Merrill, R. and G. Pedersen (1976). "Interdental osteotomy for immediate repositioning of dental-osseous elements." Journal of Oral Surgery (American Dental Association: 1965) **34**(2): 118-125.
- Moon, C.-H., J.-U. Wee, et al. (2007). "Intrusion of overerupted molars by corticotomy and orthodontic skeletal anchorage." Angle Orthodontist **77**(6): 1119-1125.
- Mossaz, C., F. Byloff, et al. (1992). "Unilateral and bilateral corticotomies for correction of maxillary transverse discrepancies." The European Journal of Orthodontics **14**(2): 110-116.
- Mostafa, Y. A., M. Mohamed Salah Fayed, et al. (2009). "Comparison of corticotomy-facilitated vs standard tooth-movement techniques in dogs with miniscrews as anchor units." American Journal of Orthodontics and Dentofacial Orthopedics **136**(4): 570-577.
- Mueller, M., T. Schilling, et al. (1991). "A systemic acceleratory phenomenon (SAP) accompanies the regional acceleratory phenomenon (RAP) during healing of a bone defect in the rat." Journal of Bone and Mineral Research **6**(4): 401-410.
- Murphy, K. G., M. T. Wilcko, et al. (2009). "Periodontal accelerated osteogenic orthodontics: a description of the surgical technique." Journal of Oral and Maxillofacial Surgery **67**(10): 2160.
- Nanci, A. (2007). Ten Cate's Oral Histology-E-Book: Development, Structure, and Function, Mosby.
- Nishimura, M., M. Chiba, et al. (2008). "Periodontal tissue activation by vibration: intermittent stimulation by resonance vibration accelerates experimental tooth movement in rats." American Journal of Orthodontics and Dentofacial Orthopedics **133**(4): 572-583.
- Oliveira, D. D., B. F. de Oliveira, et al. (2008). "Selective alveolar corticotomy to intrude overerupted molars." American Journal of Orthodontics and Dentofacial Orthopedics **133**(6): 902-908.
- Oron U., S. Ilic, et al. (2007). "Ga-As (808 nm) laser irradiation enhances ATP production in human neuronal cells in culture." Photomedicine and Laser Surgery **25**(3):180–2.
- Owman-Moll, P. and J. Kurol (1998). "The early reparative process of orthodontically induced root resorption in adolescents-location and type of tissue." The European Journal of Orthodontics **20**(6): 727-732.
- Pilon, J. J., A. M. Kuijpers-Jagtman, et al. (1996). "Magnitude of orthodontic forces and rate of bodily tooth movement. An experimental study." American Journal of Orthodontics and Dentofacial Orthopedics **110**(1): 16-23.
- Ponder, S. N., E. Benavides, et al. (2013). "Quantification of external root resorption by low- vs high-resolution cone-beam computed tomography and periapical radiography: a volumetric and linear analysis." American Journal of Orthodontics and Dentofacial Orthopedics **143**(1): 77-91.
- Proffit, W. R., H. W. Fields, et al. (2007). Contemporary Orthodontics. St. Louis, Mo., Mosby Elsevier.
- Reitan, K. (1957). "Some factors determining the evaluation of forces in orthodontics." American Journal of Orthodontics **43**(1): 32-45.
- Reitan, K. (1964). "Effects Of Force Magnitude And Direction Of Tooth Movement On Different Alveolar Bone Types*." Angle Orthodontist **34**(4): 244-255.
- Reitan, K. (1974). "Initial tissue behavior during apical root resorption." Angle Orthodontist **44**(1): 68-82.
- Reitan, K. (1985). "Biological principles and reactions." Orthodontics, current orthodontic concepts and techniques: 101-192.

- Reitan, K. and E. Kvam (1971). "Comparative behavior of human and animal tissue during experimental tooth movement." Angle Orthodontist **41**(1): 1-14.
- Ren, Y., J. C. Maltha, et al. (2004). "The rat as a model for orthodontic tooth movement—a critical review and a proposed solution." The European Journal of Orthodontics **26**(5): 483-490.
- Roberts, W. E. and E. R. Morey (1985). "Proliferation and differentiation sequence of osteoblast histogenesis under physiological conditions in rat periodontal ligament." American Journal of Anatomy **174**(2): 105-118.
- Rubin, C., A. S. Turner, et al. (2002). "Quantity and quality of trabecular bone in the femur are enhanced by a strongly anabolic, noninvasive mechanical intervention." Journal of Bone and Mineral Research **17**(2): 349-357.
- Rygh, P. (1972). "Ultrastructural cellular reactions in pressure zones of rat molar periodontium incident to orthodontic tooth movement." Acta Odontologica Scandinavica **30**(5): 575-593.
- Sameshima, G. T. and P. M. Sinclair (2001). "Predicting and preventing root resorption: Part I. Diagnostic factors." American Journal of Orthodontics and Dentofacial Orthopedics **119**(5): 505-510.
- Sameshima, G. T. and P. M. Sinclair (2001). "Predicting and preventing root resorption: Part II. Treatment factors." American Journal of Orthodontics and Dentofacial Orthopedics **119**(5): 511-515.
- Sayin, S., A. O. Bengi, et al. (2004). "Rapid canine distalization using distraction of the periodontal ligament: a preliminary clinical validation of the original technique." Angle Orthodontist **74**(3): 304-315.
- Scheideman, G. B., H. Kawamura, et al. (1985). "Wound healing after anterior and posterior subapical osteotomy." Journal of Oral and Maxillofacial Surgery **43**(6): 408-416.
- Schilling, T., M. Müller, et al. (1998). "Influence of inflammation-mediated osteopenia on the regional acceleratory phenomenon and the systemic acceleratory phenomenon during healing of a bone defect in the rat." Calcified Tissue International **63**(2): 160-166.
- Schroeder, H. E. (1986). Handbook of microscopic anatomy: The periodontium, Springer.
- Schwartz, A. M. (1932). "Tissue changes incident to tooth movement." International Orthodontic Congress **18**: 331-352.
- Schwarz, A. M. (1932). "Tissue changes incidental to orthodontic tooth movement." International Journal of Orthodontia, Oral Surgery and Radiography **18**(4): 331-352.
- Sebaoun, J., D. Ferguson, et al. (2007). "Alveolar osteotomy and rapid orthodontic treatments." L'Orthodontie Francaise **78**(3): 217-225.
- Sebaoun, J., J. Surmenian, et al. (2011). "Accelerated orthodontic treatment with piezocision: a mini-invasive alternative to conventional corticotomies." L'Orthodontie Francaise **82**(4): 311-319.
- Sebaoun, J. D., A. Kantarci, et al. (2008). "Modeling of trabecular bone and lamina dura following selective alveolar decortication in rats." Journal of Periodontology **79**(9): 1679-1688.
- Skidmore, K. J., K. J. Brook, et al. (2006). "Factors influencing treatment time in orthodontic patients." American Journal of Orthodontics and Dentofacial Orthopedics **129**(2): 230-238.
- Sousa, M., M. Scanavini, et al. (2011). "Influence of low-level laser on the speed of orthodontic movement." Photomedicine and Laser Surgery **29**(3): 191-6.
- Stark, T. M. and P. M. Sinclair (1987). "Effect of pulsed electromagnetic fields on orthodontic tooth movement." American Journal of Orthodontics and Dentofacial Orthopedics **91**(2): 91-104.

- Stenvik, A. (1970). "Pulp and dentine reactions to experimental tooth intrusion: a histologic study of the initial changes." American Journal of Orthodontics **57**(4): 370-385.
- Storey, E. and R. Smith (1952). "Force in orthodontics and its relation to tooth movement." Australian Dental Journal **56**(1): 11-18.
- Suya, H. (1991). "Corticotomy in orthodontics." Mechanical and biological basics in orthodontic therapy. Heidelberg, Germany: Huthig Buch Verlag: 207-226.
- Taylor, N. and A. Jones (1995). "Are anterior occlusal radiographs indicated to supplement panoramic radiography during an orthodontic assessment?" British Dental Journal **179**(10): 377-381.
- Teixeira, C., E. Khoo, et al. (2010). "Cytokine expression and accelerated tooth movement." Journal of Dental Research **89**(10): 1135-1141.
- Tomizuka, R., Y. Shimizu, et al. (2007). "Histological evaluation of the effects of initially light and gradually increasing force on orthodontic tooth movement." Angle Orthodontist **77**(3): 410-416.
- Trope, M. (2002). "Root resorption due to dental trauma." Endodontic topics **1**(1): 79-100.
- Verna, C., D. Zaffe, et al. (1999). "Histomorphometric study of bone reactions during orthodontic tooth movement in rats." Bone **24**(4): 371-379.
- von Böhl, M. v., J. C. Maltha, et al. (2004). "Focal hyalinization during experimental tooth movement in beagle dogs." American Journal of Orthodontics and Dentofacial Orthopedics **125**(5): 615-623.
- von Böhl, M. and A. M. Kuijpers-Jagtman (2009). "Hyalinization during orthodontic tooth movement: a systematic review on tissue reactions." The European Journal of Orthodontics **31**(1): 30-36.
- Wang, L., W. Lee, et al. (2009). "Tissue responses in corticotomy- and osteotomy-assisted tooth movements in rats: histology and immunostaining." American Journal of Orthodontics and Dentofacial Orthopedics **136**(6): 770. e771-770. e711.
- Wang, L., W. Lee, et al. (2009). "Tissue responses in corticotomy- and osteotomy-assisted tooth movements in rats: Histology and immunostaining." American Journal of Orthodontics and Dentofacial Orthopedics **136**(6): 770.e771-770.e711.
- Wierzbicki, T., T. El-Bialy, et al. (2009). "Analysis of orthodontically induced root resorption using micro-computed tomography (Micro-CT)." Angle Orthodontist **79**(1): 91-96.
- Wilcko, M. T. and W. M. Wilcko (2001). "Rapid orthodontics with alveolar reshaping: two case reports of decrowding." International Journal of Periodontics and Restorative Dentistry **21**(1): 9-19.
- Wilcko, M. T., W. M. Wilcko, et al. (2008). "An Evidence-Based Analysis of Periodontally Accelerated Orthodontic and Osteogenic Techniques: A synthesis of Scientific Perspectives." Seminars in Orthodontics **14**(4): 305-316.
- Wilcko, M. T., W. M. Wilcko, et al. (2009). "Accelerated osteogenic orthodontics technique: a 1-stage surgically facilitated rapid orthodontic technique with alveolar augmentation." Journal of Oral and Maxillofacial Surgery **67**(10): 2149-2159.
- Wilcko, W. M. and M. T. Wilcko (2013). "Accelerating tooth movement: the case for corticotomy-induced orthodontics." American Journal of Orthodontics and Dentofacial Orthopedics **144**(1): 4-12.
- Yaffe, A., N. Fine, et al. (1994). "Regional accelerated phenomenon in the mandible following mucoperiosteal flap surgery." Journal of Periodontology **65**(1): 79-83.
- Yamasaki, K. (1983). "The role of cyclic AMP, calcium, and prostaglandins in the induction of osteoclastic bone resorption associated with experimental tooth movement." Journal of Dental Research **62**(8): 877-881.

- Yamasaki, K., Y. Shibata, et al. (1982). "The effect of prostaglandins on experimental tooth movement in monkeys (*Macaca fuscata*)."
Journal of Dental Research **61**(12): 1444-1446.
- Yamasaki, K., Y. Shibata, et al. (1984). "Clinical application of prostaglandin E upon orthodontic tooth movement."
American Journal of Orthodontics **85**(6): 508-518.
- Zengo, A., R. Pawluk, et al. (1973). "Stress-induced bioelectric potentials in the dentoalveolar complex."
American Journal of Orthodontics **64**(1): 17-27.

6. Rationale of the Current Study

Research Question

Upon a review of the literature, there is an apparent need for further research in the biological processes related to corticotomy-assisted orthodontic tooth movement, in particular:

- What are the root structure changes following orthodontic tooth movement in conjunction with surgical techniques, such as flap and corticotomy procedure?
- Are there any distant root structure changes due to bony changes that occur in flap or corticotomy-assisted tooth movement?
- Are there any changes to root structures following initial tooth movement alone, flap only and corticotomy only?

Aims of the study

The aim of the present study was to evaluate the root changes in untreated and buccal orthodontic tooth movement groups, with or without adjunctive flap surgery or a corticotomy procedure in an animal model, using Micro-CT. Furthermore, a secondary aim was to evaluate if systemic changes in bone would impact on the tooth roots in these groups.

Hypotheses

The null hypotheses to be investigated are as follow:

- No difference in the root structure following orthodontic tooth movement, flap surgery, corticotomy or combinations of orthodontic tooth movement and surgery compared with a control group.
- No systemic effects on the root structure of the contralateral first molar following orthodontic tooth movement, flap surgery, corticotomy or combinations of orthodontic tooth movement and surgery compared with a control group.

Significance/contribution to the discipline

Orthodontically-Induced Inflammatory Root Resorption (OIIRR) is a relatively common outcome of orthodontic treatment and, although it is difficult to avoid, with the literature identifying a greater than 90% occurrence of root resorption, the premature loss of a tooth or teeth, due to root resorption, is relatively uncommon. Proponents for corticotomy-assisted orthodontic tooth movement claim that one of the benefits of this surgical procedure is decreased OIIRR. However, this is backed by relatively sparse research, as the primary source is case reports.

The aim of the present study is to elucidate changes in root structure following orthodontic tooth movement in conjunction with a surgical means of movement acceleration. Of particular interest will be the changes observed in the “flap with tooth movement group”, as this has not been previously investigated. Additionally, most of the animal research in this field has considered mesial and distal tooth movement, rather than in a buccal direction, which is often the case for non-extraction treatment.

With the principal mechanism of tooth movement being similar in rats and humans, a better understanding of the biological basis behind corticotomy-assisted orthodontics will allow the clinician to make more informed judgements, in particular for those patients who are already susceptible to root resorption.

7. Statement of Purpose

Minimal biological research which assesses the root structure changes following corticotomy-assisted orthodontic tooth movement, exists.

Therefore, the principal aim of the study is to investigate the root structure changes following surgical intervention to accelerate initial orthodontic tooth movement in a rat model. This will involve constant, high orthodontic force application to the maxillary first molar, allowing buccal tooth movement, over a 7-day period.

In addition to this, the study aims to investigate root structure changes that may occur in the contralateral molar tooth in this model.

The results of the study are presented in the following two papers. These have been prepared in the style of “Archives of Oral Biology”:

8. Article One

Root structure changes following buccal orthodontic tooth movement with or without corticotomy in a rat model

Nida Khan¹

¹Resident Department Orthodontics, School of Dentistry, The University of Adelaide, Adelaide, Australia.

Abstract

Background

Corticotomy is believed to induce a catabolic condition within bone and results in a transient state of osteopenia. A decrease in bone density and increase in turnover, collectively affects the rate of orthodontic tooth movement, the degree of which is directly related to the intensity and proximity of the surgical insult. The exact biological mechanism behind corticotomy-assisted tooth movement has not been fully elucidated.

Objectives

To evaluate the root changes in untreated and buccally-directed orthodontic tooth movement groups, with or without adjunctive flap surgery or a corticotomy procedure.

Methods

Thirty-six male, Sprague-Dawley rats, six to eight weeks old, were randomly assigned to three control (no surgery; flap surgery; corticotomy) and three tooth movement groups (tooth movement only; flap with tooth movement; corticotomy with tooth movement). The corticotomy cuts were carried out by making vertical incisions on the mesial aspect of the maxillary first molar that extended between the first and second maxillary molars. A constant buccal force of 0.1N was delivered to the upper right first molar over the 7 days of the experiment. The animals were euthanased, their maxillae dissected out and resin embedded before microcomputed tomography (micro CT) scans were performed. From these, the region of interest (CEJ to root apex) was outlined for each root of the first molar, on both experimental and control sides. An analysis of the region of interest was undertaken with both qualitative and quantitative measures.

Results

The results from the reconstruction of root structure in the rat molar of the experimental tooth, showed changes, in particular, in the groups with accompanying corticotomy or flap procedures with tooth movement. The reconstructed images showed a loss of structure along the length of the root in all three tooth movement groups. Quantification of the remaining root structure showed a statistically significant volumetric difference between the groups affected by the corticotomy and flap procedures with accompanying tooth movement compared with the other groups.

Conclusion

When investigating initial tooth movement in a rat model, root structure changes were evident in reconstructed micro CT images. A statistically significant decrease in root volume was evident in two of the tooth movement groups (flap with tooth movement; corticotomy with tooth movement) compared with the control groups and tooth movement only group. As this study reports only initial tooth movement using heavy forces, it cannot be concluded that corticotomy or a flap procedure in conjunction with tooth movement causes increased root resorption.

Introduction

The completion of orthodontic treatment in a timely fashion decreases the impact that orthodontics may have on a patient's lifestyle, allows for more accurate cost predictions, and decreases risks such as a decline in enthusiasm, root resorption and demineralisation (Sameshima and Sinclair 2001; Skidmore, Brook et al. 2006; Julien, Buschang et al. 2013).

In an attempt to decrease negative sequelae associated with orthodontic treatment, clinicians have favoured techniques which may reduce the overall treatment time by increasing the rate of orthodontic tooth movement. This has been undertaken via surgical or non-surgical methods. Recently, the popularisation of surgically-assisted orthodontic tooth movement, in the form of corticotomy or corticotomy-like procedures, has been advocated (Wilcko and Wilcko 2001).

The use of these procedures has been sponsored by the belief that surgical acceleration of orthodontic tooth movement may lead to reduction in treatment times, replace some orthognathic surgeries, reduce the need for extraction, provide more bony support, and decrease the rate of orthodontic relapse and root resorption (Wilcko and Wilcko 2001; Wilcko, Wilcko et al. 2008; Wilcko, Wilcko et al. 2009). However, to date, minimal biological research into this technique exists and, therefore, it is not possible to ascertain its efficacy and validity.

Orthodontically-Induced Inflammatory Root Resorption (OIIRR) is a relatively common outcome of orthodontic treatment and occurs secondary to the compression of the periodontal ligament due to orthodontic force application. If the force is great enough to totally occlude periodontal blood vessels, sterile necrosis occurs and an avascular area, called the hyalinisation zone, is produced. Through a series of cellular events, the removal of the necrotic tissue and sound tooth structure may ensue (Schwartz 1932; Reitan 1974; Brudvik and Rygh 1994).

In orthodontic research, the detection of OIIRR has been achieved primarily by radiographs, histological means (light microscopes and scanning electron microscopes), and micro-

computed tomography (Micro-CT). Micro-CT offers a reliable means of volumetric analysis. It has the ability to provide qualitative and quantitative results in 3D morphology, without anatomically interfering with tissue (Holdsworth and Thornton 2002).

Currently, very little evidence regarding OIRR in conjunction with corticotomy exists, in either human or animal studies. Most of the current evidence is of an anecdotal nature, lacking control groups, or from case reports and a case series (Wilcko and Wilcko 2001; Machado, Ferguson et al. 2002; Iino, Sakoda et al. 2006; Iino, Sakoda et al. 2007; Nowzari, Yorita et al. 2008; Wilcko and Wilcko 2013).

The principal aim of the present study therefore, was to evaluate the root changes in untreated and buccal orthodontic tooth movement groups, with or without adjunctive flap surgery or corticotomy in an animal model, using Micro-CT. The null hypothesis is that there are no differences in the root structure following orthodontic tooth movement, flap surgery, corticotomy or combinations of orthodontic tooth movement and surgery compared with a control group.

Methods and Materials

Ethics Approval

Ethics approval from The University of Adelaide Animal Ethics Committee was sought prior to commencing the experimental procedure (Project no: M-2009-172 and M-2009-172B).

Experimental Animals

The experimental procedure used 36 male Sprague-Dawley rats obtained from The University of Adelaide's Laboratory Animal Services. The animals had an average body weight of 262gms (range 169gm-367gm) and age range from 6 to 8 weeks.

All animals were housed at Animal House Medical School (The University of Adelaide) where all live animal procedures were undertaken. This included surgeries, placement of orthodontic appliance and animal sacrifice. The animals were supplied with a softened rat chow pellet and chocolate spread diet for the duration of the experiment.

Experimental Protocol

Figure 1 outlines the timeline for the experimental procedure, which was undertaken on the maxillary right first molar and spanned seven days. This was chosen as bone turnover in the rat model takes approximately six days to occur (Vignery and Baron 1980).

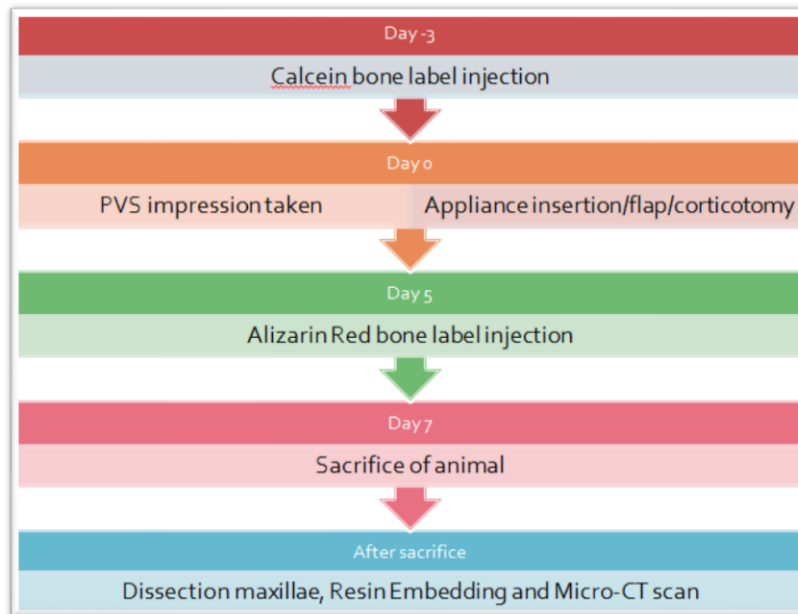


Figure 1: Timeline of experimental procedure

Study Design

The 36 rats were equally and randomly divided into six groups, three control groups and three experimental groups (Figure 2).

1. Nil intervention
2. Flap surgery
3. Corticotomy procedure only
4. Tooth movement only
5. Flap surgery and tooth movement
6. Corticotomy with tooth movement

The sample size was calculated by a bio-statistician in order to ensure significant results.

	Group 1	Group 2	Group 3	Group 4	Group 5	Group 6
Appliance	-	-	-	✓	✓	✓
Surgery	-	Flap	Corticotomy	-	Flap	Corticotomy

Figure 2: Control and experimental groups

Appliance Design

An appliance to produce buccal tooth movement was constructed and fabricated for each individual rat. From a PVS impression of the rat's maxilla, a stone model was cast and a band fitted over the incisor teeth. A 1.5mm diameter, ½ round wire (Dentaurum, Australia) was soldered to the band to act as the major connector, and a plunger/tube (0.018-in) configuration soldered to the major connector.

The active force was delivered using a 100g NiTi push coil spring (GAC Australia, Australia). This was compressed with the plunger attached to the maxillary right first molar with a stainless steel ligature 0.010-in (3M Unitek, Monrovia, USA). This ligature was attached to the plunger and passed between the contact point of the first and second molars, then tightly bound; composite resin (NeoBond, Dentsply GAC International, Bohemia, NY, USA) was used to bond the remaining ligature and plunger to the tooth. The band was cemented onto the incisors with Unitek Multi-cure Glass Ionomer (3M Unitek, Monrovia, USA) and light-cured with a halogen curing light.

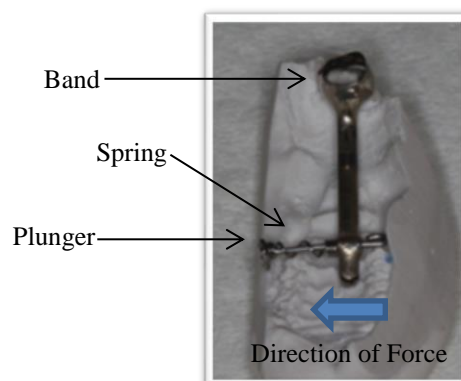


Figure 3: Appliance Design

Three days prior to the placement of the appliance, inhalation anaesthetic (isoflurane gas) was administered, polyvinylsiloxane impressions (Honigum, Gunz Dental, Australia) taken and the appliance fabricated. This technique was repeated for additional impressions, prior to and after the placement of the appliance; this was done to measure tooth displacement.

All impressions and the dissected rat maxillae were photographed using an Olympus stereomicroscope (SZX2-ILLT, Tokyo, Japan) and captured with Analysis software (v 5.1 (Build 1276), Olympus Soft Imaging Solutions, GMBH).

The insertion of the appliance was undertaken using the deep anaesthesia provided by Hypnorm/Hypnovel/Water in a 1:1:2 mix. Hypnorm® (fentanyl citrate, 0.315 mg/mL and fluanisone 10 mg/mL; Janssen-Cilag Ltd., High Wycombe, Buckinghamshire, UK) and Hypnovel® (midazolam hydrochloride, 5 mg/mL; Roche, Berne, Switzerland) were mixed separately with sterile water in a 1:1 ratio.

Additionally, each rat was given an intraperitoneal pain injection of Temgesic® (buprenorphine 0.3mg/mL; Reckitt Benckiser Healthcare Ltd., Dansom Lane, Hull, UK) at a dose of 0.05mg/mL for 1mL/Kg bodyweight.

Flap procedure

A full thickness flap, of the right maxillary molar tooth, was raised in the flap only and corticotomy groups. This was performed by creating an intrasulcular incision along the buccal surface and extended from the right maxillary first molar, anteriorly towards the edentulous area mesial to this tooth and posteriorly as a vertical incision between the roots of the first and second maxillary molars. Magnification was used as required and tissue glue, GLUture (60% 2-octyl and 40% N-butyl cyanoacrylate, Abbott Laboratories, North Chicago, USA) was used to reposition the flap and promote healing by primary intention.

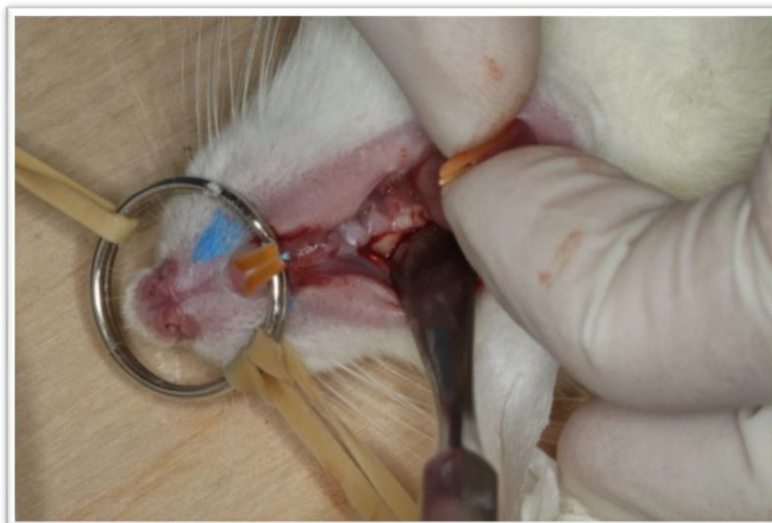

Figure 4: Reflection full thickness flap

Corticotomy procedure

The corticotomy cuts were carried out in the manner described by Wilcko et al. (2001) and performed at the same time as the appliance insertion. The corticotomy cuts were created using a slow-speed hand piece and a ½ round bur (stainless steel), a trench, the thickness and depth of the bur, was extended from apices of the first molar horizontally and mesially, to beyond the mesial root in an L shape.

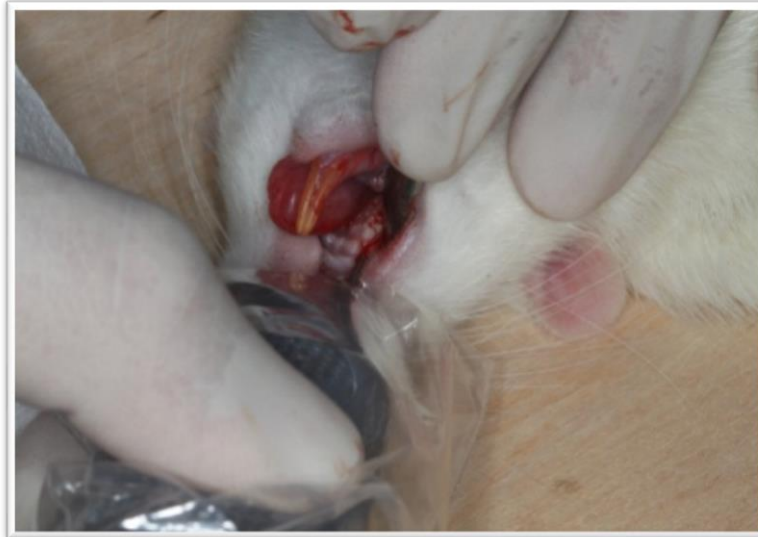

Figure 5: Corticotomy procedure being undertaken

Bone Labels

Bone labels for histomorphometry to determine the magnitude and rate of bone formation, were injected prior to rat sacrifice. Two bone labels were used, calcein® (powder, Sigma-Aldrich) and alizarin red S® (powder, Sigma-Aldrich). Bone labels were buffered to a neutral pH by dissolving in sterile 2% sodium bicarbonate solution (two grams of sodium bicarbonate with 100ml of sterile water). Three days prior to the insertion of the appliance, the calcein bone label was injected intra-peritoneally. Similarly, the alizarin red bone label was injected five days after appliance insertion. The bone labels were not used in this investigation, as they were to measure mineral apposition rate in bone (which has been undertaken in previous investigation on this model by Kim (2013)).

Sacrifice and Micro-CT

Each rat was sacrificed seven days after the placement of the appliance. This was performed using a lethal injection of Lethabarb Euthanasia (60mg/mL with 1mL/Kg of a barbiturate derivative made by Virbac (Australia) as an I.P. injection).

The appliance was removed and another PVS impression was taken. The rat maxilla was dissected out and embedded in methyl methacrylate resin following fixation and dehydration. The protocol outlined by the IMVS (SA Pathology) Bone and Joint Research Laboratory was used.

Resin infiltration was followed by micro-CT scans of all the samples using the Skyscan 1174 (Bone and Joint Research Laboratory, Institute of Medical and Veterinary Science, Adelaide) with hydroxyapatite standard blocks of 250 mg HA/cm³ and 750 mg HA/cm³, with 0.5mm aluminium filter and 22.2µm resolution scan.

The raw data collected were reconstructed using SkyScan NRecon v1.4.4 and software (Dataviewer v1.4.4) was used to reorientate the specimen and slices by operator control of sagittal, coronal and axial sections.

Analysis of Tomography

Using software CT Analyser (CTAn; v 1.12, Skyscan, Kontich, Belgium), the micro-CT slices were assessed and the area of interest outlined. The area of interest outlined was the five roots of the maxillary right molar from apex to the cemento enamel junction of the tooth, with outlining being undertaken every 10 slices (of 22.2 µm). One operator (NK), performed this task under blinded conditions. The program was used to determine the mean volume of mineralised structure in the region of interest outlined.

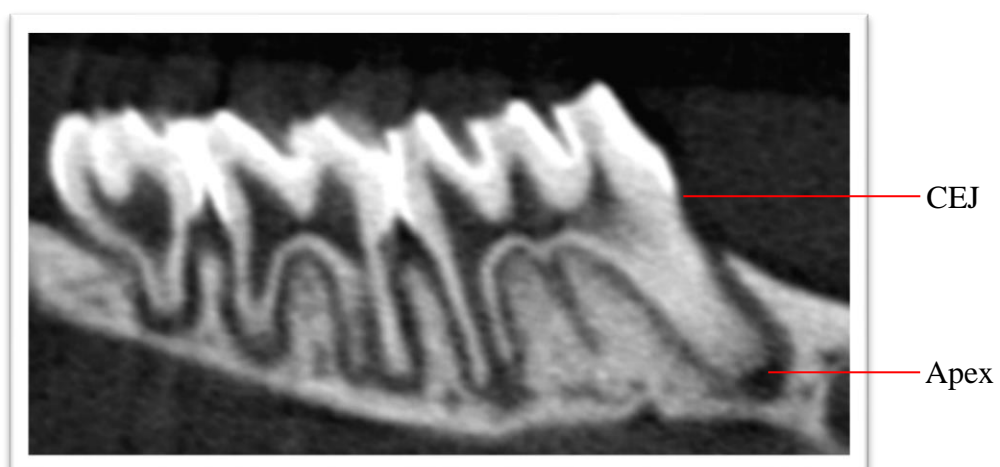


Figure 6: Slice representing measure from CEJ to root apex

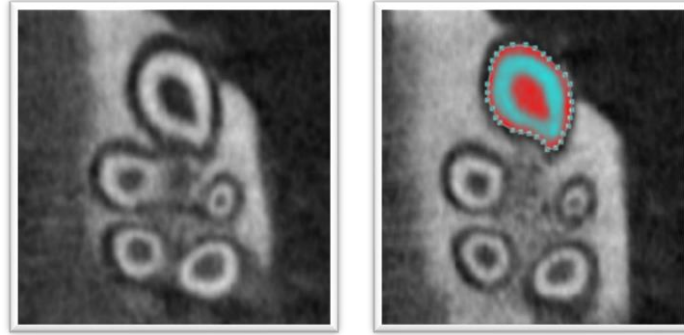


Figure 7: Sample slice of region of interest of the mesio-buccal root of the first molar

Statistical Analysis

Software SAS v9.3 (SAS Institute Inc., Cary, USA) was used for statistical analysis. The differences between the experimental groups were compared using generalised estimating equations (GEE), this was done to account for clustering within the results. A p-value of <0.05 was considered to be statistically significant.

Results

Intra-examiner reliability

The bias and random error were determined from repeat measurements of ten randomly selected first molar teeth. The bias was 0.25 % and was the mean difference of pair of measurements. The random error was 2.42% and was the standard deviation of the difference of pairs of measurement. Both were deemed as acceptable.

Hydroxyapatite Standards

A single scanning machine, with the same settings and criteria was used. Micro CT data were standardised by attaching two hydroxyapatite standard blocks to the rat maxillae during scanning. The blocks were scanned in isolation (Figure 8); a range is evident, due to variations in scanning time and orientation of standards. The results were calibrated according to these differences.

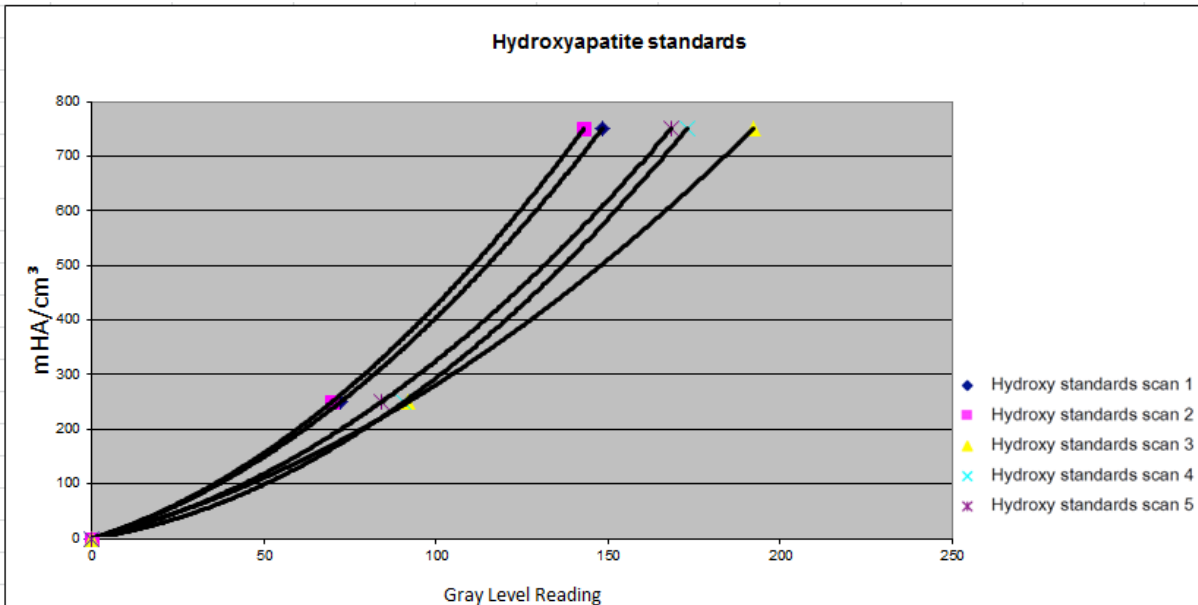


Figure 8: Line graph representing inter-scan differences of the same hydroxyapatite standards due to changes in time and orientation of standard

Structural Changes in Roots

The morphology of the root structure was examined using reconstructed images of the micro-CT images; this was performed using Paraview Software.

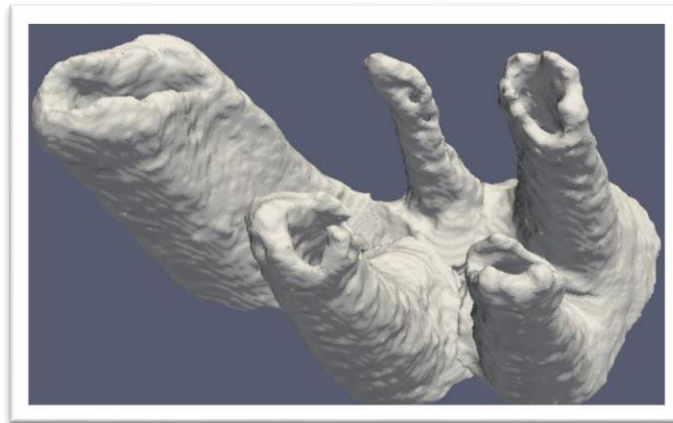

Figure 9: Reconstruction of the sagittal slices generated a 3D representation of entire root structure

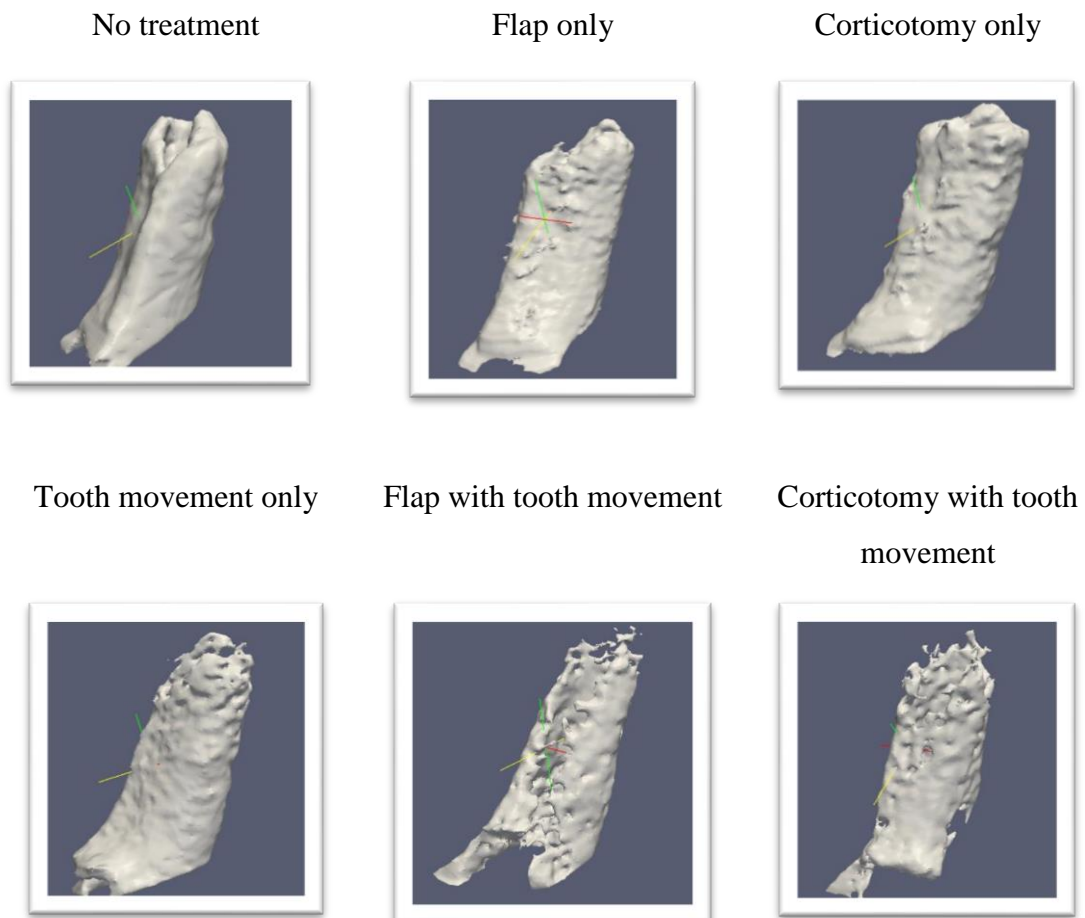


Figure 10: Sample representation of roots in each group from reconstructed sagittal slices

The reconstruction of sagittal slices of root structures, made it possible to identify the morphological differences between the groups. Root structure loss was evident in all experimental groups, with a predominance seen in the flap and corticotomy with tooth movement groups. A representative sample of roots from the first molars is provided (Figure 10).

Volumetric analysis of root structure

Volumetric analysis was undertaken using micro CT to measure the total volume of root structure that was present in each rat, within each group. Figure 11 represents the adjusted mean volumes root structure of each group.

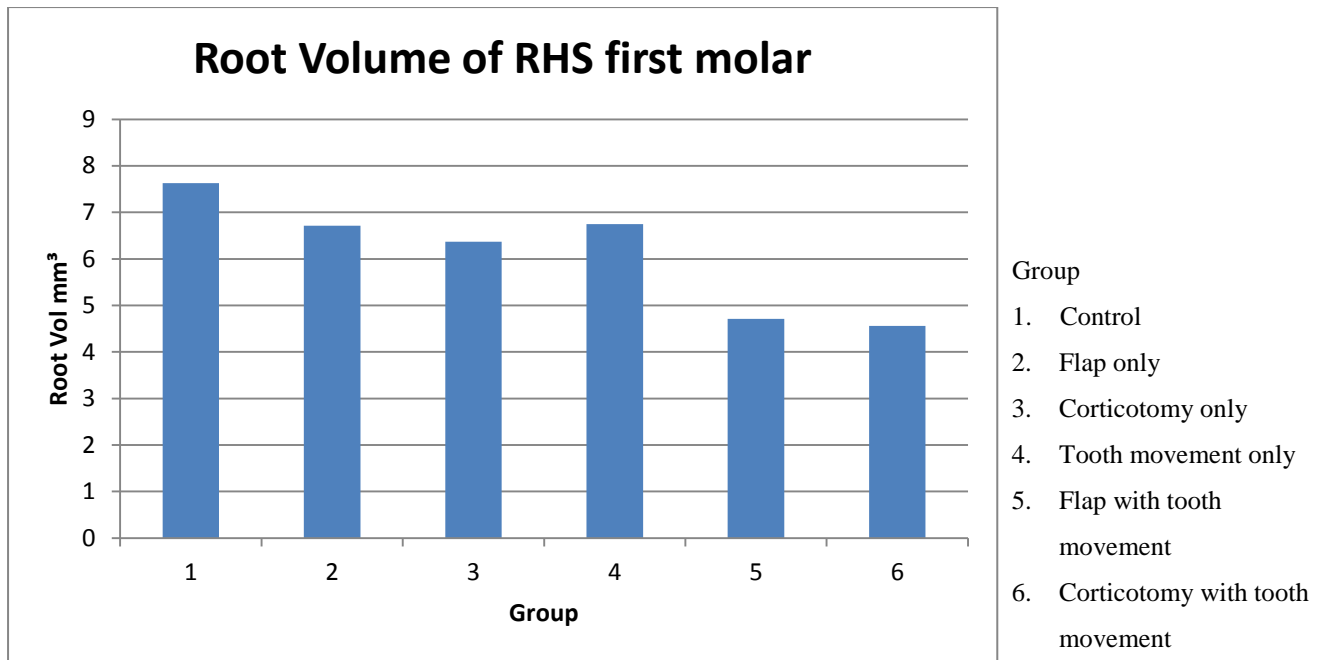


Figure 11: Adjusted mean root volumes.

Of the six groups investigated, group 6, had the lowest root volume following 7 days of tooth movement. This was followed by groups 5, 3, 4, 2 and finally the greatest root volume was seen in group 1.

The root volume of control teeth was 1.62 and 1.67 times greater than the flap with tooth movement and corticotomy with tooth movement groups, respectively.

In the three control groups (1, 2 and 3) root volume was at similar levels to that of tooth movement alone. This is reflected in the P values, in which there was no statistically significant difference amongst these groups (Table 1).

In the three tooth movement groups, significantly less root volume was evident in the with flap and corticotomy groups, compared with the tooth movement only group. Additionally, there was no significant difference between the tooth movement with flap and corticotomy groups (Table 1).

When the tooth movement with flap or corticotomy groups were compared with the control groups, there was a statistically significant difference in root volume between these groups (Table 1).

Table 1: P-values when comparing root volumes between groups

		Group				
		1	2	3	4	5
Group	2	0.35				
	3	0.28	0.58			
	4	0.39	0.79	0.62		
	5	<0.05	<0.05	<0.05	<0.05	
	6	<0.05	<0.05	<0.05	<0.05	0.73

Discussion

Orthodontic tooth movement involves the application of mechanical forces to the roots of teeth and the surrounding periodontal tissue which initiates a remodelling process facilitating the movement of teeth through alveolar bone (Krishnan and Davidovitch 2006). In the present study, the aim was to investigate root structure changes in untreated and buccal orthodontic tooth movement groups, with or without adjunctive flap surgery or corticotomy in an animal model, using Micro-CT. The null hypothesis being tested was that no differences would be observed between these groups.

Six groups, three control and three tooth movement, were formed to investigate the hypothesis. The results from the reconstruction of root structure in the rat molar of the experimental tooth showed a loss of structure along the length of the root in all three treatment groups; in particular, in the groups with corticotomy or flap accompanying tooth movement.

Quantification of the remaining root structure was undertaken by a comparison of the root volume between the groups, with the results showing a statistically significant difference in the corticotomy and flap with tooth movement groups, compared with the other groups. Of particular interest, the difference between these two groups and tooth movement only group.

An explanation for this result could be that the tooth movement only group had minimal movement of the rat molar (as found by Jong and colleagues (Jong 2012) using this sample) and had not had the opportunity to undergo observed root structure changes. Although the effect of the appliance on occlusal loading due to interference of function must also be considered, this was not observed in the tooth movement only group and so may not provide a valid argument. Although the difference between the tooth movement only group and the control groups was not appreciable in the quantification of root volume, observation of the reconstructed images, did show changes in the root structure, towards the apical region, in the tooth movement only group.

The results suggest that although surgical intervention in conjunction with tooth movement may reduce mineral bone density and bone fraction in these groups (as found by Zaw and colleagues (Zaw 2013) using this sample), and thus assist in initial phase of tooth movement, it may not prevent root resorption.

These results are not in agreement with Iino and colleagues (2007) who investigated tooth movement in conjunction with corticotomy in a dog model. Using a split mouth study, the authors found no appreciable root resorption in the tooth movement with corticotomy side, when compared with the tooth movement alone side. It was believed that the rapid tooth movement and decreased root resorption observed as a result of the corticotomy was due to less hyalinisation of the PDL which effectively decreased the lag phase in the traditional model of tooth movement described by Burstone (1962). The Burstone (1962) study however demonstrated error of the method and lacked a distinct control group.

The understanding of the cellular processes that occur in corticotomy-facilitated orthodontics was furthered by the investigation of Baloul and colleagues (2011). Using a rat model, animals were grouped into selective alveolar decortication alone, tooth movement alone and “combined” therapy (selective alveolar decortication alone and tooth movement) of the left first maxillary molar and measurements were performed at baseline (day 0: no treatment rendered) and on days 3, 7, 14, 21, 28 and 42. The authors found that increased osteoclastic cell proliferation and differentiation were translated into prolonged osteoclastic activity in the selective alveolar decortication group. It was considered that, in conjunction with increased

activity of osteoblastic cells, this led to increased bone resorption and formation during the early stages of tooth movement (Baloul, Gerstenfeld et al. 2011).

Metabolic activity in the bone was measured through the presence of RNA markers for osteoclastic cells and key osteoclastic regulators (M-CSF [macrophage colony-stimulating factor], RANKL [receptor activator of nuclear factor kappa-B ligand], OPG [osteoprotegerin], calcitonin receptor [CTR], TRACP-5b [tartrate-resistant acid phosphatase 5b], cathepsin K [Ctsk]). In the “combined therapy group”, all showed an increase in expression, indicating increased osteoclastogenesis (Baloul, Gerstenfeld et al. 2011).

More recent literature has investigated the role of osteoprotegerin (OPG), receptor activator of nuclear factor kappa B (RANK) and RANK ligand (RANKL) proteins, in physiological and orthodontic root resorption. Tyrovola and colleagues (2008) found that during orthodontic tooth movement, compression of the PDL causes expression of RANKL, whilst tension causes increased OPG synthesis. Importantly, this ratio, between RANKL and OPG, is believed to be involved in OIIRR, with greater levels of RANKL, compared with OPG, being associated with severe root resorption (Kanzaki, Chiba et al. 2002; Low, Zoellner et al. 2005; Nishijima, Yamaguchi et al. 2006; Yamaguchi, Aihara et al. 2006).

An explanation of the observed findings may be related to the increased osteoclastogenesis in the groups with corticotomy and flap, in conjunction with tooth movement, which led to root resorption and decreased root volume.

Limitations

Fundamental genetic and anatomical differences between rats and humans mean the validity of these models require thought and deliberation. In particular, the conclusions which can be drawn from the experimental findings must be tempered since rats undergo transient root resorption during physiological distal drift of molars (Reitan and Kvam 1971; Kimura, Anan et al. 2003). However, the use of rats as an experimental model has several advantages, including being relatively inexpensive, accessible, easier to handle and can provide useful information in studies evaluating orthodontic tooth movement, especially since a biological

response at the linear phase of tooth movement can be achieved with a minimum experimental period (Ren, Maltha et al. 2004).

In the present study, a particular limitation was the use of tipping movement which results in uneven force distribution along the length of the periodontal ligament and, accordingly, changes in root structure will be reflected (Baloul, Gerstenfeld et al. 2011). Also, since the experimental period was seven days, only conclusions regarding the initial phase of tooth movement can be drawn.

Further investigation into this sample should aim to provide histological validation of the observed results. Further research in this field, should aim to investigate the changes in root structure in teeth treated with a similar protocol with a longer observational period, different levels of forces and a larger sample size.

Conclusion

In conclusion, in an investigation of initial tooth movement in a rat model, root structure changes were evident in reconstructed images. These changes were reflected in the decreased root volume observed when comparing orthodontic tooth movement alone, with orthodontic tooth movement with corticotomy and flap procedures. Therefore, the null hypothesis is rejected for this model. Importantly, it should not be concluded, that corticotomy or flap procedure in conjunction with tooth movement causes increased root resorption, as this is only a reflection of initial tooth movement using heavy forces. Further histological examination to validate these results is required. A better understanding of the biological basis behind corticotomy assisted orthodontics will allow the clinician to make better clinical judgements and lead to an evidenced-based practice.

References

- Baloul, S. S., L. C. Gerstenfeld, et al. (2011). "Mechanism of action and morphologic changes in the alveolar bone in response to selective alveolar decortication–facilitated tooth movement." *American Journal of Orthodontics and Dentofacial Orthopedics* **139**(4): S83-S101.
- Brudvik, P. and P. Rygh (1994). "Multi-nucleated cells remove the main hyalinized tissue and start resorption of adjacent root surfaces." *The European Journal of Orthodontics* **16**(4): 265-273.
- Burstone, C. J. (1962). "The biomechanics of tooth movement." *Vistas in orthodontics, Lea and Febiger, Philadelphia*: 197-213.
- Holdsworth, D. W. and M. M. Thornton (2002). "Micro-CT in small animal and specimen imaging." *Trends in Biotechnology* **20**(8): S34-S39.
- Iino, S., S. Sakoda, et al. (2007). "Acceleration of orthodontic tooth movement by alveolar corticotomy in the dog." *American Journal of Orthodontics and Dentofacial Orthopedics* **131**(4): 448.e441-448.e448.
- Iino, S., S. Sakoda, et al. (2006). "An adult bimaxillary protrusion treated with corticotomy-facilitated orthodontics and titanium miniplates." *Angle Orthodontist* **76**(6): 1074-1082.
- Jong, M. J. (2012). "Corticotomy Enhanced Orthodontics." The University of Adelaide.
- Julien, K. C., P. H. Buschang, et al. (2013). "Prevalence of white spot lesion formation during orthodontic treatment." *Angle Orthodontist* **83**(4): 641-647.
- Kanzaki, H., M. Chiba, et al. (2002). "Periodontal Ligament Cells Under Mechanical Stress Induce Osteoclastogenesis by Receptor Activator of Nuclear Factor κ B Ligand Up-Regulation via Prostaglandin E2 Synthesis." *Journal of Bone and Mineral Research* **17**(2): 210-220.
- Kim, B. Y. (2013). "Corticotomy-facilitated orthodontics." The University of Adelaide.
- Kimura, R., H. Anan, et al. (2003). "Dental root resorption and repair: histology and histometry during physiological drift of rat molars." *Journal of Periodontal Research* **38**(5): 525-532.
- Krishnan, V. and Z. Davidovitch (2006). "Cellular, molecular, and tissue-level reactions to orthodontic force." *American Journal of Orthodontics and Dentofacial Orthopedics* **129**(4): 469. e461-469. e432.
- Low, E., H. Zoellner, et al. (2005). "Expression of mRNA for osteoprotegerin and receptor activator of nuclear factor kappa β ligand (RANKL) during root resorption induced by the application of heavy orthodontic forces on rat molars." *American Journal of Orthodontics and Dentofacial Orthopedics* **128**(4): 497-503.
- Machado, I., D. Ferguson, et al. (2002). "Root resorption following orthodontics with and without alveolar corticotomy." *Journal of Dental Research* **80**(1): 301.
- Nishijima, Y., M. Yamaguchi, et al. (2006). "Levels of RANKL and OPG in gingival crevicular fluid during orthodontic tooth movement and effect of compression force on releases from periodontal ligament cells in vitro." *Orthodontic and Craniofacial Research* **9**(2): 63-70.
- Nowzari, H., F. K. Yorita, et al. (2008). "Periodontally accelerated osteogenic orthodontics combined with autogenous bone grafting." *Compendium of continuing education in Dentistry* **29**(4): 200-206; quiz 207, 218.
- Reitan, K. (1974). "Initial tissue behavior during apical root resorption." *Angle Orthodontist* **44**(1): 68-82.

- Reitan, K. and E. Kvam (1971). "Comparative behavior of human and animal tissue during experimental tooth movement." Angle Orthodontist **41**(1): 1-14.
- Ren, Y., J. C. Maltha, et al. (2004). "The rat as a model for orthodontic tooth movement—a critical review and a proposed solution." The European Journal of Orthodontics **26**(5): 483-490.
- Sameshima, G. T. and P. M. Sinclair (2001). "Predicting and preventing root resorption: Part II. Treatment factors." American Journal of Orthodontics and Dentofacial Orthopedics **119**(5): 511-515.
- Schwartz, A. M. (1932). "Tissue changes incident to tooth movement." International Orthodontic Congress **18**: 331-352.
- Skidmore, K. J., K. J. Brook, et al. (2006). "Factors influencing treatment time in orthodontic patients." American Journal of Orthodontics and Dentofacial Orthopedics **129**(2): 230-238.
- Tyrovola, J. B., M. N. Spyropoulos, et al. (2008). "Root resorption and the OPG/RANKL/RANK system: a mini review." Journal of Oral Sciences **50**(4): 367-376.
- Vignery, A. and R. Baron (1980). "Dynamic histomorphometry of alveolar bone remodeling in the adult rat." The Anatomical Record **196**(2): 191-200.
- Wilcko, M. T. and W. M. Wilcko (2001). "Rapid orthodontics with alveolar reshaping: two case reports of decrowding." International Journal of Periodontics and Restorative Dentistry **21**(1): 9-19.
- Wilcko, M. T., W. M. Wilcko, et al. (2008). "An Evidence-Based Analysis of Periodontally Accelerated Orthodontic and Osteogenic Techniques: A synthesis of Scientific Perspectives." Seminars in Orthodontics **14**(4): 305-316.
- Wilcko, M. T., W. M. Wilcko, et al. (2009). "Accelerated osteogenic orthodontics technique: a 1-stage surgically facilitated rapid orthodontic technique with alveolar augmentation." Journal of Oral and Maxillofacial Surgery **67**(10): 2149-2159.
- Wilcko, W. M. and M. T. Wilcko (2013). "Accelerating tooth movement: the case for corticotomy-induced orthodontics." American Journal of Orthodontics and Dentofacial Orthopedics **144**(1): 4-12.
- Yamaguchi, M., N. Aihara, et al. (2006). "RANKL increase in compressed periodontal ligament cells from root resorption." Journal of Dental Research **85**(8): 751-756.
- Zaw, C. (2013). "Biological Response to Corticotomy-assisted Orthodontics." The University of Adelaide.

9. Article Two

Systemic root structure changes following buccal orthodontic tooth movement with or without corticotomy in a rat model

Nida Khan¹

¹Resident Department Orthodontics, School of Dentistry, The University of Adelaide, Adelaide, Australia.

Abstract

Background

Corticotomy-facilitated orthodontics is able to increase initial orthodontic tooth movement due to the Regional Acceleratory Phenomena (RAP) of bone healing. The relationship between changes in bone turnover and Orthodontically Induced Inflammatory Root Resorption (OIIRR) has been investigated, without a clear consensus.

Objectives

The aim of the present study was to investigate the systemic effect upon root structures changes following surgical interventions (flap or corticotomy) to increase initial orthodontic tooth movement.

Methods

Thirty-six male Sprague-Dawley rats were randomly divided into six groups: 3 control (control, flap only, corticotomy only) and 3 experimental (tooth movement only, tooth movement with flap and tooth movement with corticotomy). Buccal force (0.1N) was delivered to the experimental tooth (maxillary right first molar) for 7 days. A corticotomy procedure was performed on the buccal aspect of this molar, using a round slow speed bur to create an L-shaped trench subapical to the first molar and mesial to the buccal root. A three-sided, full thickness mucoperiosteal flap was raised around the experimental tooth. After 7 days, the animals were sacrificed and their maxillae were dissected, resin embedded and microcomputed tomography scans performed. The contralateral molar, was chosen to measure the systemic root structure changes. The region of interest (five roots, from CEJ to apex) of each tooth was outlined and the morphology and volumetric measurements of root structure were determined.

Results

The groups with combined surgical intervention and tooth movement showed the greatest morphological changes and the least amount of root structure volume. This was statistically significant ($P < 0.05$) when compared with all other groups. The “tooth movement only” group also showed a decreased volume of root structure and morphological changes; however, this was not statistically significant. In the three control groups, no statistically significant difference was determined and minimal-nil morphological changes were evident. No significant difference was found between the “tooth movement with flap” and “tooth movement with corticotomy” groups.

Conclusion

The data suggest that the combination of surgical intervention with orthodontic tooth movement is able to produce systemic changes, which lead to root resorption in the contralateral molar, in this rat model.

Introduction

Corticotomy-assisted orthodontic tooth movement involves a surgical procedure, in which cortical bone (buccal and/or lingual) is mechanically cut, altered or perforated (Bogoch et al. 1993). Clinical research has shown that this procedure, in conjunction with orthodontic force, can facilitate increased initial orthodontic tooth movement (Murphy et al. 2009; Wilcko et al. 2009; Aboul-Ela et al. 2011; Kim et al. 2011; Long et al. 2012). This is in agreement with animal investigations (Iino et al. 2007; Lee et al. 2008; Sebaoun et al. 2008; Kim et al. 2009; Mostafa et al. 2009; Wang et al. 2009). Although the exact biological mechanism is poorly understood, current literature suggests that the increased tooth movement witnessed in corticotomy-facilitated orthodontics coincides with the physiologic events associated with a regional acceleratory phenomena (RAP) (Wilcko and Wilcko 2001; Iino et al. 2007; Kim et al. 2009).

First coined by orthopaedic surgeon Harold Frost in 1983, a RAP increases the rapidity of a healing process, with features including accelerated bone turnover and decreased bone density. Frost believed that any regional noxious stimuli could induce this heightened response and that the duration and intensity was proportional to the extent of injury and soft tissue involvement (Frost 1983; Frost 1989).

Several mechanisms for RAP have been proposed; including, a decrease in osteoblast cell number, cell proliferation responses, neovascularization, and up-regulation of local and systemic mediators (Frost 1989; Frost 1989). Animal studies on corticotomy-facilitated orthodontics (Sebaoun et al. 2007; Baloul et al. 2011) found that an increase in tooth movement was due to decreased bone volume and increased osteoclast count and bone apposition rate revealed by fluorescent histomorphometry.

Mueller and colleagues (1991) investigated the impact of RAP on systemic bone metabolism in a rat model and found an increased mineralisation rate and formation. It was concluded that a systemic acceleratory phenomena accompanied the RAP. Furthermore, investigation by Schilling and colleagues (1998) found that a local RAP response was associated with increased systemic inflammatory markers. Verna and colleagues (1999) conducted a histomorphometric study analysing the reaction of bone in rats undergoing orthodontic tooth movement and found that the RAP extended across the whole hemimaxilla, suggesting a

systemic effect in this model. This was supported by the work of Zaw (2013) who demonstrated changes in rat alveolar bone (bone mineral density and bone fractions) on the contralateral side of corticotomy-assisted orthodontic tooth movement group.

The relationship between changes in bone turnover and orthodontically-induced inflammatory root resorption (OIIRR) have been comprehensively investigated. Primarily this has been directed at metabolic changes associated with endocrine conditions; however, no clear consensus is currently available regarding the bone turnover and OIIRR (Goldie and King 1984; Engström et al. 1988; Loberg and Engström 1994; Poumpros et al. 1994; Verna et al. 2003).

The aim of the present study was to evaluate if systemic changes in bone would impact on the roots of rat teeth whether untreated or treated (with or without adjunctive flap surgery or corticotomy) using Micro-CT. The null hypothesis is that there are no systemic effects in the root structure of the contralateral first molar following orthodontic tooth movement, flap surgery, corticotomy or combinations of orthodontic tooth movement and surgery, compared with a control group.

Methods and materials

The materials and methods related to the application of the orthodontic force and the animal model has been previously described in detail (article one) but will be briefly described in the following section.

Thirty six male Sprague-Dawley rats (average body weight 262gms; age range from 6 to 8 weeks) were obtained from The University of Adelaide's Laboratory Animal Services. All animals were housed in the Animal House Medical School (The University of Adelaide), and supplied with a diet of softened rat chow pellet and chocolate spread for the duration of the experiment.

The 36 rats were equally and randomly divided into six groups comprising three control and three experimental groups:

1. Nil intervention
2. Flap surgery

3. Corticotomy procedure only
4. Tooth movement only
5. Flap surgery and tooth movement
6. Corticotomy with tooth movement

The experimental procedure was undertaken on the maxillary right first molar and the duration of the experiment was seven days (Figure 1). The contralateral tooth (maxillary left first molar) was chosen to demonstrate systemic changes that might occur in the root structure.

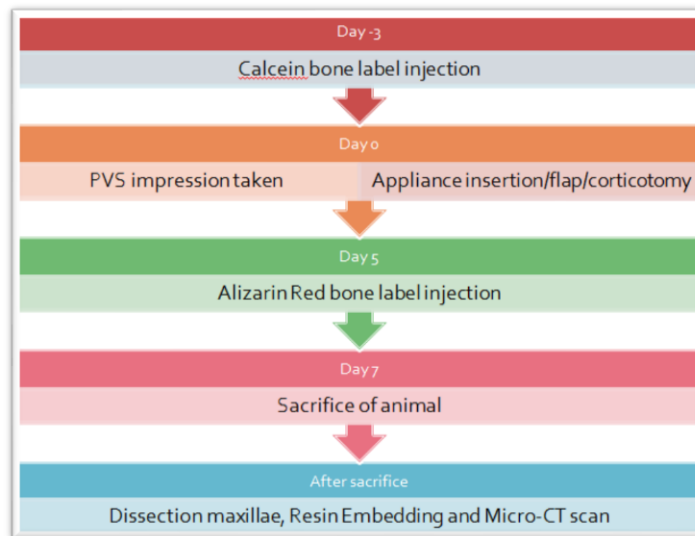


Figure 1: Timeline of experimental procedure

A customised appliance (to allow buccal tooth movement) was constructed and fabricated for each rat (Figure 2). An active force was delivered using a 0.1N NiTi push coil spring (GAC Australia, Australia) to the maxillary right first molar.

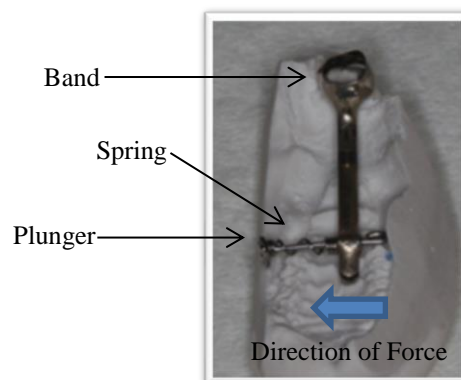


Figure 2: Appliance Design

Polyvinylsiloxane impressions (Honigum, Gunz Dental, Australia) were taken prior to appliance construction and prior to and after cementation of the appliance. All impressions and the dissected rat maxillae were photographed using an Olympus stereomicroscope (SZX2-ILLT, Tokyo, Japan) and captured with Analysis software (v 5.1 (Build 1276), Olympus Soft Imaging Solutions, GMBH).

A full thickness flap buccal to the right maxillary molar tooth was raised in the flap only and corticotomy groups. This was performed by creating an intrasulcular incision which extended along the buccal surface from the edentulous area in front of the right maxillary first molar towards the distal where a vertical incision was made between the roots of the first and second maxillary molars. Tissue glue, GLUture (60% 2-octyl and 40% N-butyl cyanoacrylate, Abbott Laboratories, North Chicago, USA) was used to reposition the flap and promote healing by primary intention.

The corticotomy cuts were carried out in the manner described by Wilcko and Wilcko (2001) and performed at the same time as appliance insertion. Corticotomy cuts (Figure 3) were created using a slow-speed hand piece and a ½ round bur (stainless steel) and a trench, the thickness and depth of the bur, was extended from the apices of the first molar horizontally and then vertically anterior to the mesial root in an L shape (Figure 4).

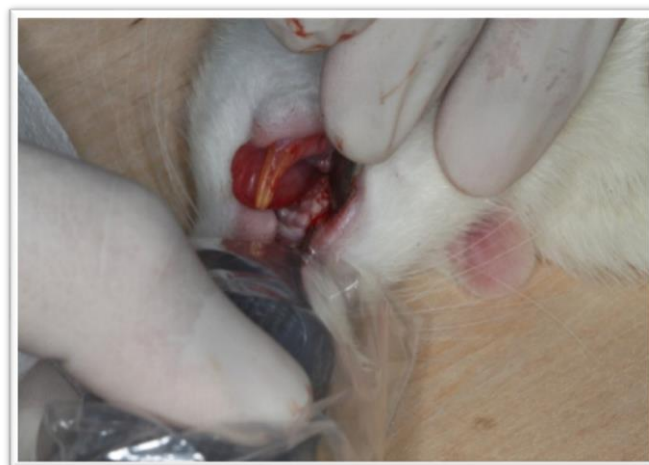

Figure 3: Corticotomy procedure being undertaken

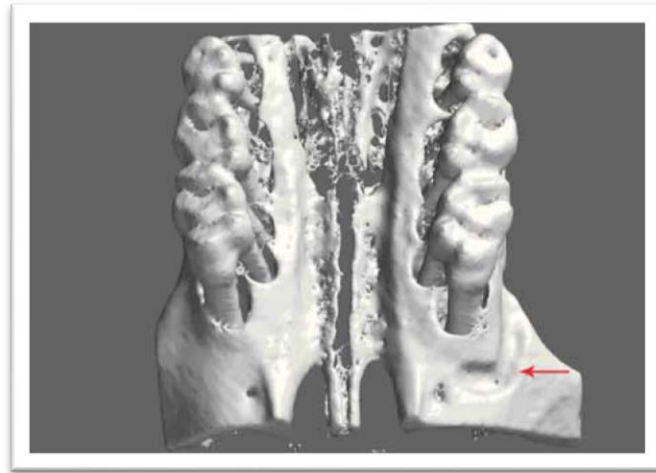


Figure 4: 3D surface rendering of corticotomy cuts

Seven days after the placement of the appliance, each rat was sacrificed, the appliance was removed and another PVS impression was taken. The rat maxilla was dissected out and embedded in methyl methacrylate resin following fixation and dehydration. This was followed by micro-computed tomography (micro-CT) scans of all the samples using a Skyscan 1174 (Bone and Joint Research Laboratory, Institute of Medical and Veterinary Science, Adelaide) with hydroxyapatite standard blocks of 250 mg HA/cm³ and 750 mg HA/cm³, with 0.5mm aluminium filter and 22.2µm resolution scan.

The raw data collected were reconstructed using SkyScan NRecon v1.4.4 and software (Dataviewer v1.4.4) was used to reorientate the specimen and slices by operator control of sagittal, coronal and axial sections.

The micro-CT slices were accessed using software CT Analyser (CTAn; v 1.12, Skyscan, Kontich, Belgium) and the area of interest outlined was the five roots of the untreated maxillary left molar from apex to the cemento-enamel junction of the tooth (Figure 5). Each root was individually outlined and this was undertaken every 10 slices (of 22.2 µm). The program was used to determine the mean volume of mineralised structure in the region of outlined interest.

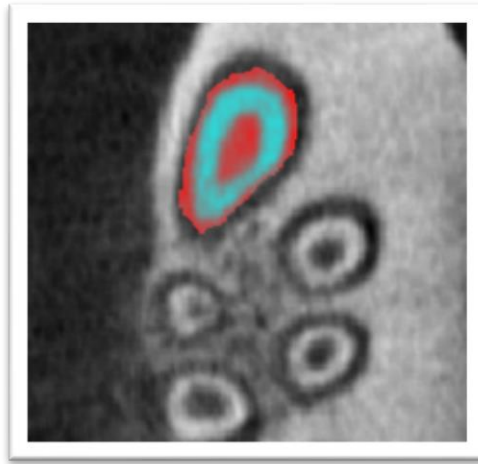


Figure 5: Sample slice of region of interest of root of first molar

Statistical analysis was undertaken using software SAS v9.3 (SAS Institute Inc., Cary, USA). The differences between the experimental groups were compared using generalised estimating equations (GEE) which accounted for clustering within the results. A p-value of <0.05 was considered to be statistically significant.

Results

Intra-examiner reliability

The error of the method was found to be negligible for all measurement. The bias and random error were assessed from repeat measurements of ten random first molar teeth. The bias was 0.25 % and was the mean difference of pair of measurements. The random error was 2.42% and was the standard deviation of the difference of pairs of measurement. Both were deemed acceptable.

Hydroxyapatite Standards

A single scanning machine with the same settings and criteria was used. Micro CT data were standardised by attaching two hydroxyapatite standard blocks to the rat maxillae during scanning. The blocks were scanned in isolation (Figure 6). A range is evident, due to variations in scanning time and orientation of the standards.

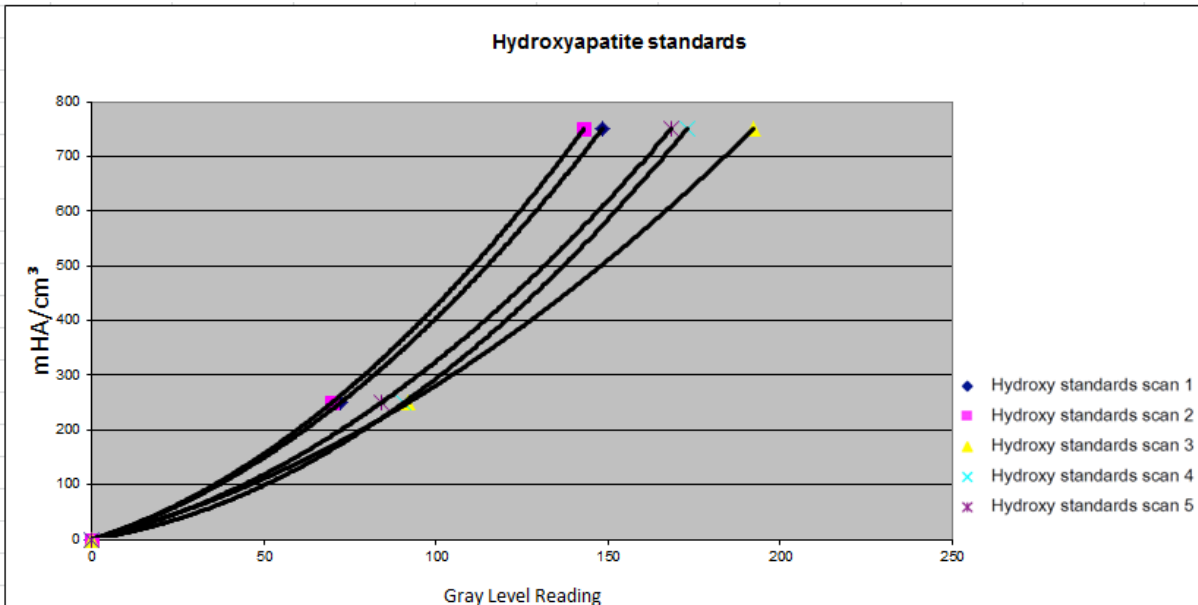
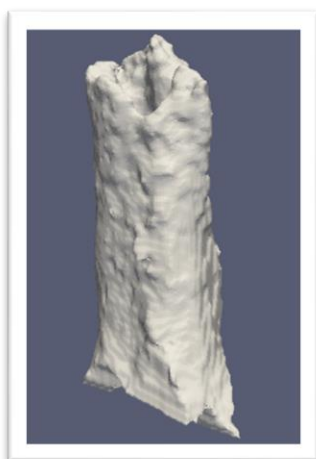

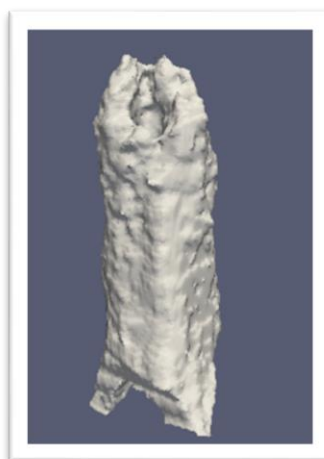Figure 6: Line graph representing inter-scan differences of the same hydroxyapatite standards due to changes in time and orientation of standard

Structural Changes in Roots

The morphology of the root structure was examined using reconstructed images of the micro CT images; this was performed using Paraview Software. From these images (Figure 7 shows representative images), root structure changes in the three control groups, were found to be minimal. However, in the tooth movement groups, it was apparent that morphological differences existed compared with the control groups. This was especially true for the flap and corticotomy groups with tooth movement.



Control



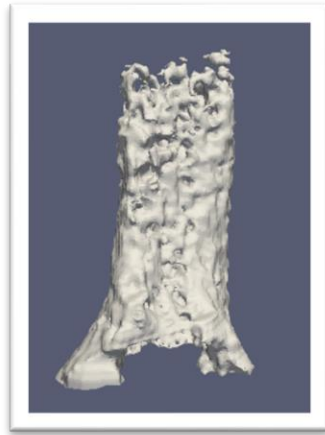Flap Only



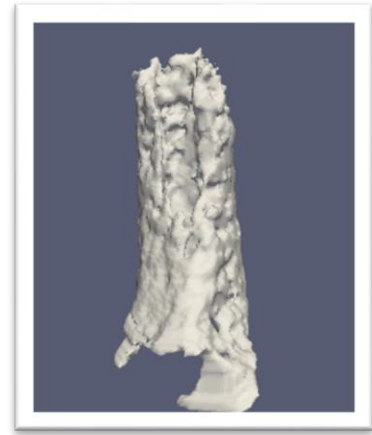Corticotomy Only



Tooth Movement Only



Flap with Tooth Movement



Corticotomy with tooth movement

Figure 7: 3D reconstructed images of representative sample of root structures (mesio-buccal) for each group from non-treated side

Volumetric Analysis

Total root structure volume was measured for each tooth and analysed in each of the respective groups. This information is represented in Figure 8, as adjusted mean volumes of root structure for each group.

From the six groups, it is evident that the three treatment groups have less root structure volume than the three control groups. The lowest mean root volume was group 6, followed by groups 5 and 4 with groups 3, 2 and 1 having similar volume. The root volume of group 6 was 1.72 times smaller than the control group.

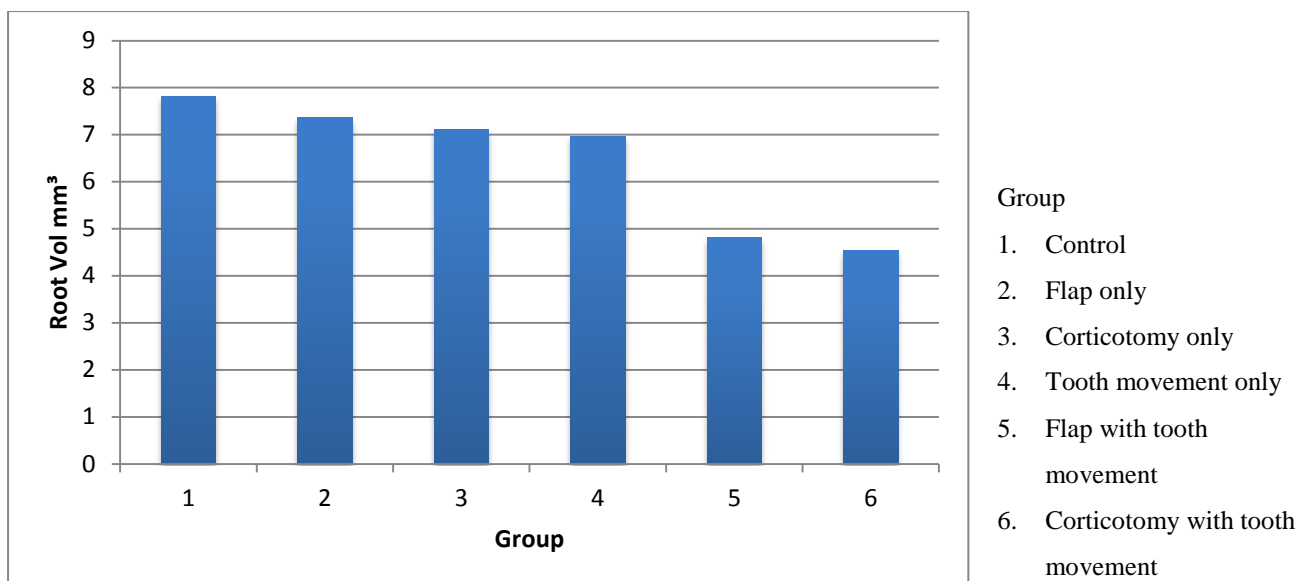


Figure 8: Adjusted mean values for root volume

Further analysis was undertaken by considering the significance of these results (Table 1).

Table 1: P-values when comparing root volumes between groups

		Group				
		1	2	3	4	5
Group	2	0.54				
	3	0.44	0.79			
	4	0.38	0.67	0.77		
	5	<0.05	<0.05	<0.05	<0.05	
	6	<0.05	<0.05	<0.05	<0.05	0.75

A significant difference is evident in the three tooth movement groups, with significantly less root volume in the tooth movement with flap and corticotomy groups, compared with the tooth movement only group. Additionally, when the tooth movement with flap or corticotomy were compared with the control groups, there was a statistically significant difference in root volume of these groups. No significant difference between the tooth movement with flap and corticotomy groups was detected.

The three control groups (1, 2 and 3) had similar root volumes and this is reflected in the P values in which there is no statistically significant difference in the results. Group 4, showed less root volume than the control groups; however, this was not significant. The difference between this group and the other two experimental groups was, however, significant at the 0.05 level.

Similar trends were observed in the experimental teeth (Article 1).

Discussion

The study aimed to investigate the systemic impact of surgical methods used to improve tooth movement on root structure. This was undertaken by assessing the contralateral root structure changes (maxillary left first molar) in a rat model. Orthodontic (buccal) force was applied to the maxillary right first molar for 7 days with three control and three treatment groups. The null hypothesis was that no difference should be observed between the six groups. The results from the study found that changes in the contralateral tooth root structure did occur, as demonstrated by reconstructed images of root structure and volumetric assessment of remaining root structure, thus rejecting the null hypothesis.

Systemic root structure changes were most notably observed in “tooth movement with flap” and “tooth movement with corticotomy” groups (group 5 and 6, respectively). These groups showed morphologic changes and significantly less root volume of the contralateral first molar (when compared with the other groups), indicating a loss of root structure. Some of these changes could be explained by disturbances created by appliance placement; however, since there was no significant difference between the “control” and the “tooth movement only” groups, this could not reliably account for all the observed changes.

In the “tooth movement only” group, morphological changes were evident in the reconstructed images and these were further quantified by the volumetric measurements which showed decreased root volume (as compared with the “control” group); however, this was not to a significant extent.

The results are suggestive that the combination of surgical intervention and tooth movement causes systemic effects which leads to changes, including effects in root structure. This is in

agreement with earlier work on the same model by Zaw (2013) who found systemic changes in the contralateral alveolar bone (decreased bone density and increased bone fraction), in these groups.

The systemic effects of increased bone turnover on root resorption have been investigated with conflicting results. Poumpros et al. (1994) examined the influence of thyroid function (increased thyroxine levels) on root resorption in a rat model with the conclusion that less root resorption was observed. This supported the work of Goldie and King (1984) who found that decreased bone density caused an increase in orthodontic tooth movement and decreased root resorption.

However, Verna et al. (2003) and Engström et al. (1988) disagreed with these findings. Verna and colleagues found that increased bone turnover, secondary to hypothyroidism, increased tooth movement, in a rat model. However, this did not influence root resorption observed with the control (tooth movement) group and the increased bone turnover group having no statistically significant difference (Verna et al. 2003).

An explanation for root structure changes in the surgical intervention with tooth movement groups may be due to the increased osteoclast numbers. In a rat study by Wang and colleagues (2009), animals were divided into 5 groups (corticotomy with tooth movement, corticotomy alone, osteotomy with tooth movement, osteotomy alone and tooth movement alone) and assessed for osteoclast and blood vessel counts at days 3, 21 and 60. At day 3, the corticotomy with tooth movement group had greater bone loss and osteoclast numbers in the alveolar bone surrounding the first molar when compared with TM-alone control group and corticotomy alone.

As expected, very little difference was observed between the control groups. The “flap only” and “corticotomy only” groups had slight decreases in root volume; however, this was not statistically significant. Reconstructed images did not show any significant morphological changes in root structure, suggesting that a systemic effect of surgical intervention alone may not be enough to cause significant root structure changes in this model. This strengthens the well-established literature regarding the association between appliance activation and recruitment of osteoclasts from hematopoietic tissues (Zhou et al. 1997; Tsay et al. 1999; Rody et al. 2001). Sebaoun and colleagues (2007) demonstrated that corticotomy alone could

induce increased localised turnover of alveolar spongiosa. This was supported by Wang and colleagues (2009) who found that osteoclast recruitment increased in the corticotomy alone group. However, this was at a much lower level when combined with tooth movement.

Conclusion

In conclusion, when investigating the application of constant heavy forces in a rat model over a 7 day period, the combination of surgical intervention to assist in orthodontic tooth movement causes systemic effects which leads to qualitative and quantitative changes in the contralateral root structure. No significant differences were apparent between the differing surgical interventions.

References

- Aboul-Ela, S. M. B. E.-D., A. R. El-Beialy, et al. (2011). "Miniscrew implant-supported maxillary canine retraction with and without corticotomy-facilitated orthodontics." *American Journal of Orthodontics and Dentofacial Orthopedics* **139**(2): 252-259.
- Baloul, S. S., L. C. Gerstenfeld, et al. (2011). "Mechanism of action and morphologic changes in the alveolar bone in response to selective alveolar decortication-facilitated tooth movement." *American Journal of Orthodontics and Dentofacial Orthopedics* **139**(4): S83-S101.
- Bogoch, E., N. Gschwend, et al. (1993). "Healing of cancellous bone osteotomy in rabbits—Part I: Regulation of bone volume and the regional acceleratory phenomenon in normal bone." *Journal of Orthopaedic Research* **11**(2): 285-291.
- Engström, C., G. Granström, et al. (1988). "Effect of orthodontic force on periodontal tissue metabolism a histologic and biochemical study in normal and hypocalcemic young rats." *American Journal of Orthodontics and Dentofacial Orthopedics* **93**(6): 486-495.
- Frost, H. M. (1983). "The regional acceleratory phenomenon: a review." *Henry Ford Hosp Medical Journal* **31**(1): 3-9.
- Frost, H. (1989). "The biology of fracture healing: an overview for clinicians. Part I." *Clinical Orthopaedics and Related Research* **248**: 283-293.
- Goldie, R. S. and G. J. King (1984). "Root resorption and tooth movement in orthodontically treated, calcium-deficient, and lactating rats." *American Journal of Orthodontics* **85**(5): 424-430.
- Iino, S., S. Sakoda, et al. (2007). "Acceleration of orthodontic tooth movement by alveolar corticotomy in the dog." *American Journal of Orthodontics and Dentofacial Orthopedics* **131**(4): 448.e441-448.e448.
- Kim, H. S., Y. J. Lee, et al. (2011). "Histologic assessment of the biological effects after speedy surgical orthodontics in a beagle animal model: a preliminary study." *The Korean Journal of Orthodontics* **41**(5): 361-370.
- Kim, S.-J., Y.-G. Park, et al. (2009). "Effects of Corticision on paradental remodeling in orthodontic tooth movement." *Angle Orthodontist* **79**(2): 284-291.
- Lee, W., G. Karapetyan, et al. (2008). "Corticotomy-/osteotomy-assisted tooth movement microCTs differ." *Journal of Dental Research* **87**(9): 861-867.
- Loberg, E. L. and C. Engström (1994). "Thyroid administration to reduce root resorption." *Angle Orthodontist* **64**(5): 395-399.
- Long, H., U. Pyakurel, et al. (2012). "Interventions for accelerating orthodontic tooth movement: a systematic review." *Angle Orthodontist* **83**(1): 164-171.
- Mostafa, Y. A., M. Mohamed Salah Fayed, et al. (2009). "Comparison of corticotomy-facilitated vs standard tooth-movement techniques in dogs with miniscrews as anchor units." *American Journal of Orthodontics and Dentofacial Orthopedics* **136**(4): 570-577.
- Mueller, M., T. Schilling, et al. (1991). "A systemic acceleratory phenomenon (SAP) accompanies the regional acceleratory phenomenon (RAP) during healing of a bone defect in the rat." *Journal of Bone and Mineral Research* **6**(4): 401-410.
- Murphy, K. G., M. T. Wilcko, et al. (2009). "Periodontal accelerated osteogenic orthodontics: a description of the surgical technique." *Journal of Oral and Maxillofacial Surgery* **67**(10): 2160.
- Poumpros, E., E. Loberg, et al. (1994). "Thyroid function and root resorption." *Angle Orthodontist* **64**(5): 389-393.

- Rody, W. J., G. J. King, et al. (2001). "Osteoclast recruitment to sites of compression in orthodontic tooth movement." American Journal of Orthodontics and Dentofacial Orthopedics **120**(5): 477-489.
- Schilling, T., M. Müller, et al. (1998). "Influence of inflammation-mediated osteopenia on the regional acceleratory phenomenon and the systemic acceleratory phenomenon during healing of a bone defect in the rat." Calcified tissue international **63**(2): 160-166.
- Sebaoun, J., D. Ferguson, et al. (2007). "[Alveolar osteotomy and rapid orthodontic treatments]." L'Orthodontie française **78**(3): 217-225.
- Sebaoun, J. D., A. Kantarci, et al. (2008). "Modeling of trabecular bone and lamina dura following selective alveolar decortication in rats." Journal of Periodontology **79**(9): 1679-1688.
- Tsay, T. P., M.-H. Chen, et al. (1999). "Osteoclast activation and recruitment after application of orthodontic force." American Journal of Orthodontics and Dentofacial Orthopedics **115**(3): 323-330.
- Verna, C., D. Zaffe, et al. (1999). "Histomorphometric study of bone reactions during orthodontic tooth movement in rats." Bone **24**(4): 371-379.
- Verna, C., M. Dalstra, et al. (2003). "Bone turnover rate in rats does not influence root resorption induced by orthodontic treatment." The European Journal of Orthodontics **25**(4): 359-363.
- Wang, L., W. Lee, et al. (2009). "Tissue responses in corticotomy-and osteotomy-assisted tooth movements in rats: histology and immunostaining." American Journal of Orthodontics and Dentofacial Orthopedics **136**(6): 770. e771-770. e711.
- Wilcko, M. T. and W. M. Wilcko (2001). "Rapid orthodontics with alveolar reshaping: two case reports of decrowding." International Journal of Periodontics and Restorative Dentistry **21**(1): 9-19.
- Wilcko, M. T., W. M. Wilcko, et al. (2009). "Accelerated osteogenic orthodontics technique: a 1-stage surgically facilitated rapid orthodontic technique with alveolar augmentation." Journal of Oral and Maxillofacial Surgery **67**(10): 2149-2159.
- Zaw, C. (2013). "Biological Response to Corticotomy-assisted Orthodontics." The University of Adelaide.
- Zhou, D., B. Hughes, et al. (1997). "Histomorphometric and biochemical study of osteoclasts at orthodontic compression sites in the rat during indomethacin inhibition." Archives of Oral Biology **42**(10): 717-726

10. Concluding Remarks

Orthodontically-induced inflammatory root resorption (OIIRR) is a relatively common outcome of orthodontic treatment. Proponents for corticotomy-assisted orthodontic tooth movement claim that one of the benefits of this surgical procedure is decreased OIIRR. However, this is backed by relatively little research with the primary source being case reports. The aim of the present study was to elucidate changes in root structure following orthodontic tooth movement in conjunction with surgical means to accelerate it. Of particular interest were the changes witnessed in “flap with tooth movement group” as this has not been previously investigated. Additionally, most of the animal research in this field has considered mesial and distal tooth movement, rather than buccal, which is often the case for non-extraction treatment.

Root structure changes were evident in micro-CT reconstructed images. These changes were reflected in the decreased root volume observed when comparing orthodontic tooth movement alone with orthodontic tooth movement with corticotomy and flap procedures, in both experimental and non-experimental sides. The results suggest that, although surgical intervention in conjunction with tooth movement may reduce mineral bone density and bone fraction in these groups and thus assist in the initial phase of tooth movement, it may not prevent root resorption. Furthermore, the combination of surgical intervention and tooth movement has the capacity to cause systemic root structure changes in the rat model.

Further investigation into this sample should aim to provide histological validation of the observed results. Further research in this field, should aim to investigate the changes in root structure in teeth treated with a similar protocol with a longer observational period, different levels of forces and a larger sample size.