

## SUBMITTED VERSION

***This is the pre-peer reviewed version of the following article:***

Robert J Casson, Glyn Chidlow, John PM Wood, Jonathan G Crowston, and Ivan Goldberg  
**Definition of glaucoma: clinical and experimental concepts**  
Clinical and Experimental Ophthalmology, 2012; 40(4):341-349

***which has been published in final form at <http://dx.doi.org/10.1111/j.1442-9071.2012.02773.x>***

***This article may be used for non-commercial purposes in accordance with Wiley Terms and Conditions for Use of Self-Archived Versions."***

© 2012 The Authors.

### PERMISSIONS

<https://authorservices.wiley.com/author-resources/Journal-Authors/licensing/self-archiving.html>

#### Submitted (preprint) Version

The submitted version of an article is the author's version that has not been peer-reviewed, nor had any value added to it by Wiley (such as formatting or copy editing).

The submitted version may be placed on:

- the author's personal website
- the author's company/institutional repository or archive
- not for profit subject-based preprint servers or repositories

Self-archiving of the submitted version is not subject to an embargo period. We recommend including an acknowledgement of acceptance for publication and, following the final publication, authors may wish to include the following notice on the first page:

***"This is the pre-peer reviewed version of the following article: [FULL CITE], which has been published in final form at [Link to final article using the DOI]. This article may be used for non-commercial purposes in accordance with Wiley Terms and Conditions for Use of Self-Archived Versions."***

The version posted may not be updated or replaced with the accepted version (except as provided below) or the final published version (the Version of Record).

There is no obligation upon authors to remove preprints posted to not for profit preprint servers prior to submission.

**7 September 2020**

<http://hdl.handle.net/2440/73277>

## The Definition of Glaucoma: Clinical and Experimental Concepts

<sup>1</sup>R.J. Casson

<sup>1</sup>G. Chidlow,

<sup>1</sup>J.P.M. Wood

<sup>2</sup>JG Crowston,

<sup>3</sup>I Goldberg

<sup>1</sup>South Australian Institute of Ophthalmology, Hanson Institute & Adelaide University.

<sup>2</sup>Centre for Eye Research Australia & University of Melbourne

<sup>3</sup>Eye Associates, Glaucoma Services, Sydney Eye Hospital, University of Sydney

Address correspondence to:

Professor Robert J. Casson

South Australian Institute of Ophthalmology

Level 8, East Wing,

Royal Adelaide Hospital,

South Australia,

Australia 5000.

Ph. 61 8 82222729

Fax 61 8 2222747

Email: [robert.casson@adelaide.edu.au](mailto:robert.casson@adelaide.edu.au)

Abstract word count: 157

Text word count: 4277

Financial or commercial conflicts: nil

## **Abstract**

Glaucoma is a term describing a group of ocular disorders with multi-factorial aetiology united by a clinically characteristic intraocular pressure-associated optic neuropathy. It is not a single entity and is sometimes referred to in the plural as the glaucomas. All forms are potentially progressive and can lead to blindness. The diverse conditions that comprise glaucoma are united by a clinically characteristic optic neuropathy, known as glaucomatous optic neuropathy (GON). Evidence suggests that the primary site of neurological injury is at the optic nerve head (ONH). This single fact, sometimes conceptualized as common end-organ damage, enables the conditions to be grouped, irrespective of the causal mechanism(s). The term experimental glaucoma implies model resemblance to the human condition. We propose that “experimental glaucoma” be restricted to animal models with demonstrable features of GON and/or evidence of a primary axonopathy at the ONH. A fundamental inadequacy in this framework is any reference to the pathogenesis of GON, which remains unclear.

Glaucoma (in all its forms) is the leading cause of irreversible blindness worldwide<sup>1, 2</sup> and is a research focus for many ophthalmic and neuroscience-based laboratories. The definition of its most common subtype, primary open-angle glaucoma (POAG), appears inconsistently in the literature,<sup>3</sup> and the fact that *glaucoma* refers to a group of related conditions may not be appreciated by non-clinicians. The status of intraocular pressure (IOP) as a defining characteristic of glaucoma has evolved over time. From the latter part of the 19<sup>th</sup> century until the last quarter of the 20<sup>th</sup> century, IOP was a defining characteristic of glaucoma; however, the recognition of elevated IOP in the absence of “glaucomatous optic neuropathy” (GON) and conversely GON in the absence of an elevated IOP relegated IOP to risk factor status rather than a defining feature. Although the American Academy of Ophthalmology in its Preferred Practice Patterns® series does not define glaucoma *per se*, it currently views IOP as a risk factor, amongst many, for primary open-angle glaucoma (POAG).<sup>4</sup> But IOP reduction remains the only treatment strategy for all types of glaucoma. The decade-old epidemiological definition has enhanced management, with its angle-closure-related nomenclature widely adopted clinically.<sup>5</sup> Others have called for a consensus definition for clinical glaucoma.<sup>3, 6</sup> Herein, we have set out to provide a framework for conceptualizing glaucoma. We do not claim that a consensus has been reached amongst the glaucoma community, nor do we intend this to be the last word on the matter. We are optimistic that an improved understanding of glaucoma will lead to better definitions, and we adhere to the viewpoint that it is prudent to be skeptical of any scientific paradigm.

## **Clinical Glaucoma**

### **The definition of glaucoma**

The concise definition of glaucoma is as follows:

*Glaucoma is a term describing a group of ocular disorders with multi-factorial aetiology united by a clinically characteristic intraocular pressure-associated optic neuropathy.*

This characteristic optic neuropathy is termed "glaucomatous optic neuropathy" (GON), and includes structural and functional features. While it has the advantage of concision, this definition is circular. Arguably it is an "analytical proposition", which whilst true, contains no useful information: the subject is contained within the predicate, and it logically distills to "glaucoma is glaucoma".

To avoid this conundrum we must contain the "characteristics" within the definition.

Hence, the formal definition is as follows:

*Glaucoma describes a group of ocular disorders of multi-factorial aetiology united by a clinically characteristic optic neuropathy with potentially progressive, clinically visible changes at the optic nerve head (ONH), comprising focal or generalized thinning of the neuroretinal rim with excavation and enlargement of the optic cup, representing neurodegeneration of retinal ganglion cell axons and deformation of the lamina cribrosa; corresponding diffuse and localized nerve-fibre-bundle pattern visual field loss may not be detectable in early stages; while visual acuity is initially spared, progression can lead to complete loss of vision; the constellation of clinical features is diagnostic.*

In practice, the concise definition is adequate, but requires that the communicator and the intended audience understand the characteristics that define glaucoma.

## **Definition of Basic Glaucoma Subtypes and Associated Conditions**

*Elevated intraocular pressure (IOP)* means the IOP exceeds the 97.5<sup>th</sup> percentile for the population under consideration.

*Ocular Hypertension (OHT)* describes the condition where the IOP is elevated, for any or no apparent reason, but glaucomatous optic neuropathy is not detectable.

*Glaucoma Suspect* describes an eye (or individual) with features suggestive of glaucoma, but where the clinician believes that there is insufficient evidence to commit to a diagnosis of glaucoma.

*Primary Open-angle Glaucoma (POAG)* is a singular subtype of glaucoma with an open angle, and if the IOP is elevated, no cause is found.

*Normal Tension/Pressure Glaucoma (NTG/NPG)* may be singular subtype of POAG where the IOP is never observed to be elevated.

*Secondary Open-angle glaucoma (SOAG)* refers to a collection of glaucomas with an open-angle, the IOP is or has been elevated and a cause for the elevated IOP is clinically evident.

*Primary Angle-closure glaucoma (PACG)* is a singular subtype of glaucoma with anatomical iridotrabecular contact, potentially involving multiple mechanisms; the IOP is always elevated at some stage.

*Secondary angle-closure glaucoma (SACG)* is a collective subtype of glaucoma with iridotrabecular contact not from any form of anatomical predisposition: an alternative pathological mechanism is responsible; and the IOP is or has been elevated at some stage.

### **Notes on the definitions**

The definition that we have offered for glaucoma contains the salient features of the condition:

“Glaucoma” is not a single entity. It refers to a group of ocular disorders; as these disorders have diverse features, perhaps “the glaucomas” as a plural would be better. The term applies equally well to an eye or to an individual. If one eye of an individual has glaucoma, the individual is considered

to have glaucoma. Even though we use the terms “glaucoma” and “glaucomas” interchangeably, it is preferable to specify the particular subtype under consideration.

IOP is a continuous biological variable and follows an approximately Gaussian distribution in the population, with rightward skewing. An elevated IOP is a statistical concept with clinical implications and defined as an IOP greater than the 97.5<sup>th</sup> percentile for the population; this accords with epidemiological definitions.<sup>5</sup> By defining elevated IOP in percentile terms, it doesn't matter if the distribution is not Gaussian. But including an elevated IOP as a part of the definition presents a problem; GON occurs in individuals who never have a recorded IOP that is elevated: so-called "normal tension glaucoma" (NTG). Whilst, the existence of NTG as a separate disease process is disputed,<sup>7</sup> reducing the IOP in individuals with NTG can modify the natural history of the disease<sup>8</sup>; therefore, we believe it is accurate to say that even NTG is "associated with IOP". Similarly, IOP reduction attenuates the progression of POAG.<sup>9</sup> All secondary glaucoma subtypes have an elevated IOP.<sup>5</sup> IOP reduction is the only current evidence-based treatment strategy for all types of glaucoma, including NTG, (a study to determine the efficacy of IOP reduction for secondary glaucoma would be unethical because there is no clinical equipoise.<sup>5</sup>) Hence, glaucoma in all its forms is associated with IOP, albeit the IOP is not statistically elevated in the case of NTG.

All forms are potentially progressive and can lead to blindness. We prefer "potentially progressive" rather than "progressive" because this term makes three important points: (1) Glaucoma can be diagnosed in the absence of documented progression. On first presentation of an individual with characteristic features of GON, it is unnecessary to wait for observed changes to confirm diagnosis. Changes are assumed to have occurred as part of the natural history of the condition. (2) Progression is not always observed as part of the natural history. Temporary conditions may occur at the ONH which produce GON, but which do not progress. This is a theoretical possibility with empirical support. In the Normal Tension Glaucoma Study, approximately 50% of untreated individuals had localized visual field deterioration by 7 years.<sup>10</sup> Similarly, a period of elevated IOP may produce



GON that does not progress if the IOP naturally returns to normal. However, it seems prudent for clinicians to regard all glaucoma as potentially progressive. (3) The notion that glaucoma is potentially, but not inevitably, progressive underlies the current treatment paradigm: IOP reduction can attenuate, if not halt, disease progression in both “high pressure” and “normal pressure” glaucomas.<sup>8,9</sup>

The diverse conditions that comprise the glaucomas are united by a clinically characteristic optic neuropathy. This single fact, sometimes conceptualized as common end-organ damage,<sup>5</sup> enables the conditions to be grouped, irrespective of the causal mechanism(s). Clinically visible changes occur at the ONH. “Optic disc” is broadly synonymous with the ONH, but “disc” suggests a two-dimensional structure as viewed with the monocular direct ophthalmoscope. “ONH” is a better description for the 3-dimensional structure. Overwhelmingly, clinical impression sites the primary pathology at the ONH. This notion is supported by limited experimental evidence. Quigley et al demonstrated axonal transport obstruction at the ONH in a primate model of glaucoma.<sup>11, 12</sup> In a rodent model (DBA/2J mouse), the earliest observable pathology may occur at the distal RGC axon (closer to its synapse),<sup>13</sup> but the site of primary injury in this glaucoma model is the (ONH).<sup>14, 15</sup> Hence GON is primarily an “optic nerve headopathy”.

Excavation and enlargement of the optic cup, with focal or generalized thinning of the neuroretinal rim are the hallmarks of GON. These characteristic changes to the ONH take some time to develop. An acute obstruction of blood flow to the ONH typically does not produce changes characteristic of GON. Thus an IOP sufficiently elevated to obstruct ONH blood flow acutely will produce an ischaemic optic neuropathy, not glaucoma.

Pathologically, there is neurodegeneration of all RGC compartments. Because glaucoma is a primary axonopathy at the ONH, the RGC axons are the first cellular compartment to be involved. There is a surprising paucity of published histological analysis of the retina, but the available evidence indicates that the RGC dendrites are affected at an early stage of the disease<sup>16, 17</sup> with eventual loss

of RGC bodies that has features of apoptotic cell death.<sup>18</sup> Degeneration of the lateral geniculate nucleus has been reported in human and experimental primate glaucoma.<sup>19-21</sup> Recently, functional magnetic resonance imaging has demonstrated changes in the higher visual centres in human and experimental glaucoma.<sup>22, 23</sup> Oddly, there is only a single case report of a post-mortem examination on a human brain from a patient with glaucoma, demonstrating trans-synaptic degeneration back to the visual cortex.<sup>24</sup> Whether or not other neuronal cell types are affected in human glaucoma requires further study.

The RGC axons are not the only structures affected at the ONH. Deformation and particularly backward bowing of the lamina cribrosa are visible clinically. There is evidence for astrocyte<sup>25-27</sup> and microglial activation at the ONH.<sup>28-31</sup> Morphological connective tissue changes at the ONH associated with excavation and undermining of the rim are almost pathognomonic.<sup>32</sup>

That structural changes to neurones produce corresponding functional changes is fundamental to the pathophysiological interpretation of clinical findings. At some level, structure must correlate with function. But this correlation is not always demonstrable clinically. The apparent dissociation between structure and function sometimes observed may result from different scales of measurement for these parameters and/or the lack of highly sensitive functional tests with narrow inter-subject variability. The associated functional deficits include scotomata in a pre-chiasmal, nerve fibre bundle-type distribution, matching the observed changes at the ONH. Diffuse suppression of the visual field may be an early feature of glaucoma. Localized field defects typically begin in the mid-peripheral or paracentral region. Other functional deficits, including a reduction in contrast sensitivity are observed but less frequently clinically tested.<sup>33, 34</sup> Snellen visual acuity deteriorates late in the disease. Whether glaucomatous visual dysfunction can precede any structural glaucomatous change at the ONH is unclear. Evidence against this assertion comes from our collective clinical experience: we rarely, or perhaps never, witness definitively glaucomatous visual fields in the absence of any possible glaucomatous ONH changes. But evidence supporting this

assertion comes from the Ocular Hypertension Treatment Study (OHTS). Participants on enrollment had an elevated IOP, but optic discs deemed "normal by 2 independent, masked, certified readers at the Optic Disc Reading Center". The study was designed to determine the effect of IOP reduction compared with the natural history based on the proportion of individuals converting to GON. The first sign of GON in 41.7% of the treated group and 32.6% of the control group was visual field change. Does this mean visual field changes frequently precede optic disc changes in glaucoma development? Perhaps the OHTS results are more likely from many participants having borderline optic discs at enrollment, which in the presence of normal fields were arguably normal, but by Bayesian-type clinical decision making, in the presence of early glaucomatous field changes would be reconsidered as glaucomatous. Why structural changes should be the harbinger of functional changes, rather than vice versa is unclear. Given that RGCs may be "sick" and dysfunctional before they undergo degeneration and severe structural change, it is surprising that functional deficits are not routinely seen before loss of axons. As we do not, perhaps our functional measurements do not capture early functional changes.

Any of the glaucomas can progress to complete loss of vision, and as a group, the glaucomas are the leading cause of irreversible blindness worldwide.

Glaucoma is a clinical diagnosis. No investigations are required to make the diagnosis, but ONH imaging techniques, including stereophotography, complement the clinical diagnosis and provide permanent records, which on repetition, can be assessed for change. Diagnosis is based on the constellation of clinical features. This point has important ramifications: (1) there is no single measurement that can capture all glaucoma. (2) it cannot be diagnosed by an untrained observer. (3) the clinical evidence in support of a diagnosis of glaucoma is not an all or none phenomenon.

### **The Diagnosis of Glaucoma**

The structural features of GON coupled with the functional features form the basis for the diagnosis. Rarely, both the structural and functional features of GON can be mimicked by other conditions. A

masquerading condition cannot be ruled out with mathematical certainty.<sup>35</sup> Hence, based on the evidence available, a clinician develops a degree of belief about the likelihood that a patient does have glaucoma. This is a form of Bayesian decision making. Because this degree of belief is on a continuum, exemplified by the design of a recent online GON teaching tool,<sup>36</sup> the more relevant information that the clinician has, the better. Because clinicians may interpret data differently, levels of belief about the glaucoma status of individuals may differ amongst clinicians. This variability and the subjective nature of the Bayesian approach gives rise to the clinical entity of “glaucoma suspects”. These individuals have an increased risk of developing GON. They comprise a considerable portion of clinical practice. For clinical trials where the glaucoma status of a subject is critical information, either at the outset or endpoint, the gold standard diagnostic assessment may be the consensus of expert opinion.

As glaucoma is a clinical diagnosis, the diagnosis focuses on assessing whether or not the characteristic features of GON are present. Additional information, if available, is not disregarded. In reality, the prudent clinician evaluates all the available evidence and formulates a degree of belief about glaucoma likelihood. This probability ranges from nil to certainty (or at least beyond reasonable doubt). This is a Bayesian interpretation rather than a frequentist interpretation of probability. In practice, reasonable management decisions do not necessarily require a definitive diagnosis. A patient may be managed appropriately on the “balance of probabilities”. However, for the purposes of clinical studies it is often necessary to categorize individuals as having “definite glaucoma”. The minimum possible clinical information that is both necessary and sufficient to commit to a diagnosis of glaucoma is based on the observation of characteristic ONH features or consistent, characteristic visual field changes of GON, in the absence of another explanation for the functional defect.

An example of how complementary information can affect the diagnosis of glaucoma is provided by the methodology of the Early Manifest Glaucoma Treatment Study (EMGTS).<sup>9</sup> Entry criteria were

largely based on the presence of repeatable “glaucomatous visual field defects”, which were “outside normal limits”, but the methodology also stated: “A “borderline” classification (on Humphrey perimetry 24-2 testing) was acceptable only if obvious localized glaucomatous optic disc cupping was present in an area corresponding to the visual field defect.” Hence, the Investigators permitted knowledge of the ONH appearance to influence the interpretation of the visual fields. In Bayesian terms, the posterior probability (of glaucoma) was influenced by the prior probability (the visual fields) and new data (the ONH appearance). Because glaucoma is defined in terms of GON, information about other clinical features of the condition is not necessary for diagnosis, but, in practice, it does influence diagnostic decision making. Although for the purposes of a clinical study, it may be reasonable to restrict clinical information to the features of GON, this is an artificial situation that does not reflect clinical practice. For example, knowledge of the IOP, or family history of an individual could reasonably influence interpretation of the ONH appearance and/or visual fields. It is a popular misconception that the IOP is irrelevant to the diagnosis: it is not necessary, but it is not irrelevant.

### **Basic Classification of the Glaucomas**

Perhaps the most clinically useful classification of the glaucomas is that devised by Barkan which divides glaucoma into angle-closure or open-angle.<sup>37</sup> A further subdivision produces either primary or secondary glaucomas (Figure 1). In the latter, the clinician detects an "elevated IOP" during the disease and finds a cause; in the former, if the IOP is ever elevated, no cause is found. The division of primary glaucoma into open-or angle closure sub-types is an extremely useful clinical distinction; however, primary angle-closure glaucoma (PACG) is more aptly categorized with the secondary glaucomas: the angle is closed owing to an anatomical predisposition creating iridotrabecular contact (ITC). In secondary angle-closure glaucomas, the cause for the ITC is deemed to be pathological rather than anatomical, but the terminology has a historical basis, not a logical one.

The association between primary open-angle glaucoma (POAG) and IOP is more tenuous, because of the subset with NTG. Additionally, we have another large group of individuals with elevated IOP, but no GON: so-called ocular hypertension (OHT). The definition of glaucoma circumvents OHT because in OHT, GON is not present. OHT is a risk factor for GON, and the higher the IOP, the greater the risk. Hence, the principal problem in our taxonomy of glaucoma is NTG. All other forms of glaucoma have an elevated IOP, at least at some point during the disease. Entrenched in the ophthalmic lexicon, it requires a definition, remaining cognizant that its existence is disputed.<sup>7</sup> We accept the merit of Wilson's "Myth of 21" in reference to an IOP of 21 mmHg as a cut off separating POAG from NTG,<sup>7</sup> but conversely, note that POAG at low IOPs may have clinical features different from POAG at elevated IOPs.<sup>35, 38, 39</sup> Whether the features of NTG are distinct enough to warrant it to be called a "disease" in its own right is controversial.

The glaucomas are further clinically divided into acute and chronic based on duration. The dividing line seems arbitrary, but in humans, a chronic disease is measured in months to years rather than days to weeks. Primary and secondary glaucoma can be acute or chronic. If glaucoma requires GON as a defining criterion, what is the minimum time required for recognizable GON to develop.

We conceptualize a "space" (confined by IOP and time) within which GON can develop bounded at the earliest duration by the minimum time taken to develop features of GON and bounded by an upper limit of IOP beyond which the ONH is rendered acutely ischaemic and beyond which the features of GON do not develop. The longest duration over which GON can develop is simply bounded by the age at death. The minimum IOP at which GON can develop within a lifetime remains unclear.

How does ONH appearance after an acute IOP elevation differ from that after chronic elevation? Clinically, an acute IOP elevation often produces pallor without excavation; by definition, this is not glaucoma. The little evidence available supports this impression.<sup>40-42</sup> Thus an attack of acute angle closure in the absence of any chronic IOP elevation frequently will not produce GON and, if it

doesn't, by definition is not one of the glaucomas. It must be considered as a related but distinct condition.

## **Experimental Glaucoma**

### *Experimental models of relevance to glaucoma*

A model is a representation of reality. Although the concept of “validity” in science is somewhat nebulous, the scientific community generally considers a model as valid if it mimics what it is supposed to. Researchers “validate” their own model and the medical literature abounds with publications describing validation of various experimental models. Whether a model is clinically useful is a different matter. A biological model is useful clinically if information derived from it could improve patient outcomes. This includes models designed to improve understanding of biological mechanisms and to test treatments. A *Drosophila* model of glaucoma genetics is potentially valid and useful if it generates data relevant to the genetics of human glaucoma. A wide variety of experimental models could be relevant to glaucoma. They could be both useful and valid in the context of glaucoma; it would be imprudent to ignore information from a model because it did not resemble the clinical condition. However, extrapolation of laboratory-based data to the human situation can be problematic.

### *Models of RGC injury*

Models of RGC injury, both *in vitro* and *in vivo*, are routine in neuroscience research. Researchers using these models often assert the possible relevance to human glaucoma of data thus generated. Because glaucoma is a RGC axonopathy, this conclusion seems reasonable, but conversely, the data *may not* have relevance. The possible irrelevance to clinical disease of lab-based models, particularly in *in vitro* models is particularly evident in the neurological field; it highlights the frustrated translation of laboratory-based neuroprotection to human conditions.

As argued by Weinreb and Lindsey, *in vitro* models often provide methodological advantages and are a powerful research tool, but are generally less relevant to clinical glaucoma than *in vivo* models.

43

### *What is Experimental Glaucoma?*

The term experimental glaucoma implies model resemblance to the human condition. Although *Drosophila* research could be a valid and useful model for certain aspects of glaucoma, it should not be regarded as experimental glaucoma. Similarly, *in vitro* models do not merit the term experimental glaucoma. An experimental model of glaucoma (as apposed to a model with relevance to glaucoma) should fit the definition of glaucoma we have suggested. Experimental models meeting that standard are rare, but naturally occurring glaucoma in animals is well described.

### *Naturally occurring “glaucoma” in animals*

Naturally occurring sight-threatening, IOP-associated ocular disease is not unique to humans. Veterinarians use the term “glaucoma” to describe a form of eye disease recognized in several types of domesticated animals, and characterized by IOP-induced optic nerve degeneration (and in some species retinal degeneration).<sup>44, 45</sup> All these conditions are associated with an elevated IOP and almost all have an underlying cause for the elevated IOP or are associated with angle closure and thus could be considered “secondary glaucomas”. The beagle dog has a primary open-angle glaucoma with no antecedent cause for IOP elevation, but its features and natural history are different from human POAG.<sup>46</sup> Cupping of the ONH is a characteristic feature; naturally occurring GON in certain animal species with a well-formed lamina cribrosa resembles human GON. To our knowledge, NTG has never been reported in any animal other than humans. Although the naturally occurring glaucoma in a colony of purpose-bred beagle dogs has been considered as a potential model for human glaucoma,<sup>47</sup> most glaucoma animal research has been on models of induced glaucoma in rodents, rabbits and primates.



### *GON in experimental models*

A number of animal models of glaucoma have been developed over the past 3 decades, some more successful than others. The most common strategy to induce features of GON has been to elevate the IOP, but chronic optic nerve ischaemia has also been reported to cause GON in rabbits and primates. The primate model involving trabecular meshwork laser was developed in the 1970s and still remains a viable model,<sup>48, 49</sup> but has largely been replaced by logistically and ethically more appealing rodent models. A variety of techniques have been used to obstruct the trabecular meshwork in rats, including cautery of “episcleral” veins,<sup>50</sup> translimbal laser photocoagulation,<sup>51, 52</sup> and hypertonic saline injection.<sup>53</sup> More recently, micobeads have been used to obstruct the meshwork and placement improved by using paramagnetic beads.<sup>53</sup> Of these, only translimbal laser has stood the test of time and is in widespread use. Hypertonic saline injection appears to be effective, but is technically demanding and not widely used. Magnetic beads remain relatively untested. Surgically induced mouse models of experimental glaucoma have been reported, but do not appear to have been widely adopted.<sup>54-56</sup> A number of genetic mouse models exist,<sup>57</sup> and the most well-characterized is the DBA/2J mouse.<sup>58</sup> This mouse develops an age-related elevation of IOP and RGC loss. Its chronicity is appealing in terms of its resemblance to human glaucoma, but non-glaucomatous pathological retinal features have been described,<sup>59</sup> making its relevance unclear.

Although animal models of experimental glaucoma can be used to test hypotheses, we must be careful about drawing inferences about human glaucoma pathogenesis and potential therapy from animal models. If a successful treatment in an animal model of elevated IOP (not counting reduction of IOP) could be translated to human glaucoma then the model would have been convincingly validated. To our knowledge, this challenge remains unmet.

ONH changes described as “cupping” have been reported in rats,<sup>60-62</sup> mice<sup>61, 63</sup>, rabbits,<sup>64, 65</sup> and most convincingly in primates.<sup>43, 66</sup> The most common strategy to induce features of GON has been to elevate the IOP, but chronic optic nerve ischaemia has also been reported to cause GON in rabbits

and primates.<sup>64, 65</sup> We propose “experimental glaucoma” be restricted to animal models with demonstrable features of GON and/or evidence of a primary axonopathy at the ONH.<sup>14</sup>

In conclusion, we provide a conceptual framework for clinical and experimental glaucomas. A fundamental inadequacy in this framework is any reference to the pathogenesis of GON. However, pathogenesis remains poorly understood and cannot be incorporated into a definition. Conceivably, a unifying mechanism may ultimately explain all GON. Conversely, a raft of mechanisms may be responsible for GON and the notion of glaucoma as a single concept may become a historical curiosity. Either way, we look forward to a better understanding.

## References

1. Dandona L, Dandona R. What is the global burden of visual impairment? *BMC Med* 2006; **4**: 6.
2. Quigley HA. Number of people with glaucoma worldwide. *Br J Ophthalmol* 1996; **80**: 389-93.
3. Bathija R, Gupta N, Zangwill L, Weinreb RN. Changing definition of glaucoma. *J Glaucoma* 1998; **7**: 165-9.
4. American Academy of Ophthalmology Glaucoma Panel. Preferred Practice Pattern® Guidelines. Primary Open-Angle Glaucoma. San Francisco, CA: American Academy of Ophthalmology; 2010. Available at: <http://www.aao.org/ppp>. Accessed 12/1/12.
5. Foster PJ, Buhrmann R, Quigley HA, Johnson GJ. The definition and classification of glaucoma in prevalence surveys. *Br J Ophthalmol* 2002; **86**: 238-42.
6. Kroese M, Burton H. Primary open angle glaucoma. The need for a consensus case definition. *J Epidemiol Community Health* 2003; **57**: 752-4.
7. Wilson MR. The myth of "21". *J Glaucoma* 1997; **6**: 75-7.
8. Comparison of glaucomatous progression between untreated patients with normal-tension glaucoma and patients with therapeutically reduced intraocular pressures. Collaborative Normal-Tension Glaucoma Study Group. *Am J Ophthalmol* 1998; **126**: 487-97.
9. Heijl A, Leske MC, Bengtsson B, Hyman L, Hussein M. Reduction of intraocular pressure and glaucoma progression: results from the Early Manifest Glaucoma Trial. *Arch Ophthalmol* 2002; **120**: 1268-79.
10. Anderson DR, Drance SM, Schulzer M. Natural history of normal-tension glaucoma. *Ophthalmology* 2001; **108**: 247-53.
11. Quigley HA, Addicks EM. Chronic experimental glaucoma in primates. I. Production of elevated intraocular pressure by anterior chamber injection of autologous ghost red blood cells. *Invest Ophthalmol Vis Sci* 1980; **19**: 126-36.

12. Quigley HA, Guy J, Anderson DR. Blockade of rapid axonal transport. Effect of intraocular pressure elevation in primate optic nerve. *Arch Ophthalmol* 1979; **97**: 525-31.
13. Crish SD, Sappington RM, Inman DM, Horner PJ, Calkins DJ. Distal axonopathy with structural persistence in glaucomatous neurodegeneration. *Proc Natl Acad Sci U S A* 2010; **107**: 5196-201.
14. Chidlow G, Ebnetter A, Wood JP, Casson RJ. The optic nerve head is the site of axonal transport disruption, axonal cytoskeleton damage and putative axonal regeneration failure in a rat model of glaucoma. *Acta Neuropathol* 2011; **121**: 737-51.
15. Howell GR, Libby RT, Jakobs TC, Smith RS, Phalan FC, Barter JW *et al.* Axons of retinal ganglion cells are insulted in the optic nerve early in DBA/2J glaucoma. *J Cell Biol* 2007; **179**: 1523-37.
16. Leung CK, Weinreb RN, Li ZW, Liu S, Lindsey JD, Choi *Net al.* Long-term in vivo imaging and measurement of dendritic shrinkage of retinal ganglion cells. *Invest Ophthalmol Vis Sci* 2011; **52**: 1539-47.
17. Weber AJ, Kaufman PL, Hubbard WC. Morphology of single ganglion cells in the glaucomatous primate retina. *Invest Ophthalmol Vis Sci* 1998; **39**: 2304-20.
18. Kerrigan LA, Zack DJ, Quigley HA, Smith SD, Pease ME. TUNEL-positive ganglion cells in human primary open-angle glaucoma. *Arch Ophthalmol* 1997; **115**: 1031-5.
19. Gupta N, Greenberg G, de Tilly LN, Gray B, Polemidiotis M, Yucel YH. Atrophy of the lateral geniculate nucleus in human glaucoma detected by magnetic resonance imaging. *Br J Ophthalmol* 2009; **93**: 56-60.
20. Gupta N, Yucel YH. What changes can we expect in the brain of glaucoma patients? *Surv Ophthalmol* 2007; **52 Suppl 2**: S122-6.
21. Gupta N, Yucel YH. Brain changes in glaucoma. *Eur J Ophthalmol* 2003; **13 Suppl 3**: S32-5.
22. Fiedorowicz M, Dyda W, Rejdak R, Grieb P. Magnetic resonance in studies of glaucoma. *Med Sci Mon: Int Med J Exp & Clin Res* 2011; **17**: RA227-32.

23. Qing G, Zhang S, Wang B, Wang N. Functional MRI signal changes in primary visual cortex corresponding to the central normal visual field of patients with primary open-angle glaucoma. *Invest Ophthalmol Vis Sci* 2010; **51**: 4627-34.
24. Gupta N, Ang LC, Noel de Tilly L, Bidaisee L, Yucel YH. Human glaucoma and neural degeneration in intracranial optic nerve, lateral geniculate nucleus, and visual cortex. *Br J Ophthalmol* 2006; **90**: 674-8.
25. Hernandez MR. The optic nerve head in glaucoma: role of astrocytes in tissue remodeling. *Prog Retin Eye Res* 2000; **19**: 297-321.
26. Hernandez MR, Pena JD. The optic nerve head in glaucomatous optic neuropathy. *Arch Ophthalmol* 1997; **115**: 389-95.
27. Morgan JE. Optic nerve head structure in glaucoma: astrocytes as mediators of axonal damage. *Eye (Lond)* 2000; **14 ( Pt 3B)**: 437-44.
28. Bosco A, Inman DM, Steele MR, Wu G, Soto I, Marsh-Armstrong *Net al.* Reduced retina microglial activation and improved optic nerve integrity with minocycline treatment in the DBA/2J mouse model of glaucoma. *Invest Ophthalmol Vis Sci* 2008; **49**: 1437-46.
29. Ebnetter A, Casson RJ, Wood JP, Chidlow G. Microglial activation in the visual pathway in experimental glaucoma: spatiotemporal characterization and correlation with axonal injury. *Invest Ophthalmol Vis Sci* 2010; **51**: 6448-60.
30. Neufeld AH. Microglia in the optic nerve head and the region of parapapillary chorioretinal atrophy in glaucoma. *Arch Ophthalmol* 1999; **117**: 1050-6.
31. Yuan L, Neufeld AH. Activated microglia in the human glaucomatous optic nerve head. *J Neurosci Res* 2001; **64**: 523-32.
32. Quigley HA, Hohman RM, Addicks EM, Massof RW, Green WR. Morphologic changes in the lamina cribrosa correlated with neural loss in open-angle glaucoma. *Am J Ophthalmol* 1983; **95**: 673-91.

33. Lahav K, Levkovitch-Verbin H, Belkin M, Glovinsky Y, Polat U. Reduced mesopic and photopic foveal contrast sensitivity in glaucoma. *Archives of ophthalmology* 2011; **129**: 16-22.
34. Stamper RL, Hsu-Winges C, Sopher M. Arden contrast sensitivity testing in glaucoma. *Archives of ophthalmology* 1982; **100**: 947-50.
35. Greenfield DS. Glaucomatous versus nonglaucomatous optic disc cupping: clinical differentiation. *Semin Ophthalmol* 1999; **14**: 95-108.
36. Kong YX, Coote MA, O'Neill EC, Gurria LU, Xie J, Garway-Heath *Det al.* Glaucomatous optic neuropathy evaluation project: a standardized internet system for assessing skills in optic disc examination. *Clin Experiment Ophthalmol* 2011; **39**: 308-17.
37. Barkan O. Glaucoma: classification, causes, and surgical control. Results of microgonioscopic research *Am J Ophthalmol* 1938; **2**: 1099–1114.
38. Drance S, Anderson DR, Schulzer M. Risk factors for progression of visual field abnormalities in normal-tension glaucoma. *Am J Ophthalmol* 2001; **131**: 699-708.
39. Flammer J, Mozaffarieh M. What is the present pathogenetic concept of glaucomatous optic neuropathy? *Surv Ophthalmol* 2007; **52 Suppl 2**: S162-73.
40. Aung T, Looi AL, Chew PT. The visual field following acute primary angle closure. *Acta Ophthalmol Scand* 2001; **79**: 298-300.
41. Douglas GR, Drance SM, Schulzer M. The visual field and nerve head in angle-closure glaucoma. A comparison of the effects of acute and chronic angle closure. *Arch Ophthalmol* 1975; **93**: 409-11.
42. Radius RL, Maumenee AE. Visual field changes following acute elevation of intraocular pressure. *Trans Sect Ophthalmol Am Acad Ophthalmol Otolaryngol* 1977; **83**: 61-8.
43. Weinreb RN, Lindsey JD. The importance of models in glaucoma research. *J Glaucoma* 2005; **14**: 302-4.
44. Brooks DE. Glaucoma in the dog and cat. *Vet Clin North Am Small Anim Pract* 1990; **20**: 775-97.

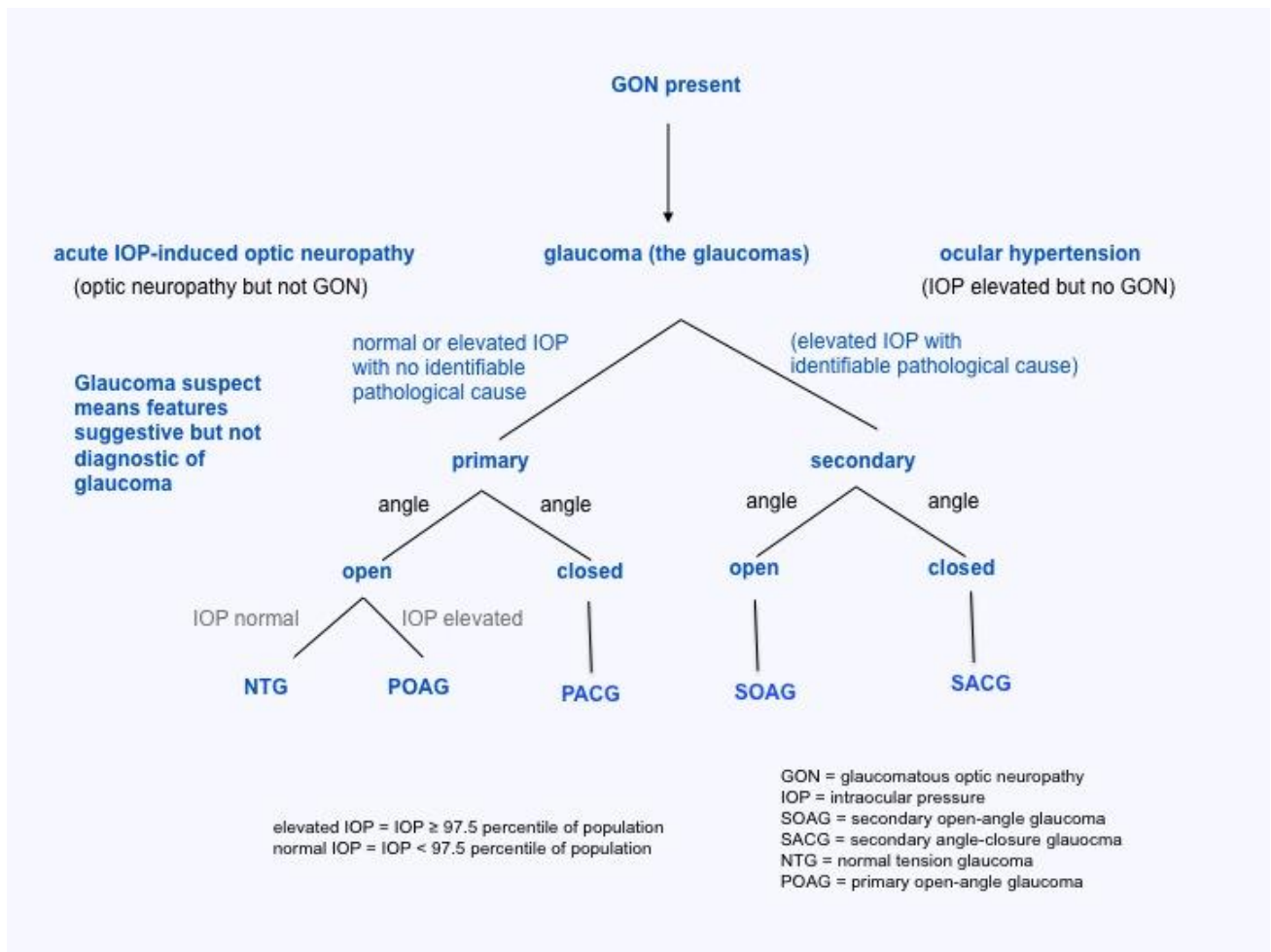
45. Wilkie DA. Equine glaucoma: state of the art. *Equine Vet J Suppl* 2010; 62-8.
46. Gelatt KN, Gum GG, Gwin RM, Bromberg NM, Merideth RE, Samuelson DA. Primary open angle glaucoma: inherited primary open angle glaucoma in the beagle. *Am J Pathol* 1981; **102**: 292-5.
47. Brooks DE, Strubbe DT, Kubilis PS, MacKay EO, Samuelson DA, Gelatt KN. Histomorphometry of the optic nerves of normal dogs and dogs with hereditary glaucoma. *Exp Eye Res* 1995; **60**: 71-89.
48. Gaasterland D, Tanishima T, Kuwabara T. Axoplasmic flow during chronic experimental glaucoma. 1. Light and electron microscopic studies of the monkey optic nervehead during development of glaucomatous cupping. *Investigative ophthalmology & visual science* 1978; **17**: 838-46.
49. Gaasterland D, Kupfer C. Experimental glaucoma in the rhesus monkey. *Investigative ophthalmology* 1974; **13**: 455-7.
50. Shareef SR, Garcia-Valenzuela E, Salierno A, Walsh J, Sharma SC. Chronic ocular hypertension following episcleral venous occlusion in rats. *Experimental eye research* 1995; **61**: 379-82.
51. Levkovitch-Verbin H, Quigley HA, Martin KR, Valenta D, Baumrind LA, Pease ME. Translimbal laser photocoagulation to the trabecular meshwork as a model of glaucoma in rats. *Investigative ophthalmology & visual science* 2002; **43**: 402-10.
52. Ueda J, Sawaguchi S, Hanyu T, Yaoeda K, Fukuchi T, Abe *Het al.* Experimental glaucoma model in the rat induced by laser trabecular photocoagulation after an intracameral injection of India ink. *Japanese journal of ophthalmology* 1998; **42**: 337-44.
53. Morrison JC, Moore CG, Deppmeier LM, Gold BG, Meshul CK, Johnson EC. A rat model of chronic pressure-induced optic nerve damage. *Experimental eye research* 1997; **64**: 85-96.
54. Grozdanic SD, Betts DM, Sakaguchi DS, Allbaugh RA, Kwon YH, Kardon RH. Laser-induced mouse model of chronic ocular hypertension. *Investigative ophthalmology & visual science* 2003; **44**: 4337-46.

55. Ji J, Chang P, Pennesi ME, Yang Z, Zhang J, Li Det al. Effects of elevated intraocular pressure on mouse retinal ganglion cells. *Vision research* 2005; **45**: 169-79.
56. Aihara M, Lindsey JD, Weinreb RN. Experimental mouse ocular hypertension: establishment of the model. *Investigative ophthalmology & visual science* 2003; **44**: 4314-20.
57. Johnson TV, Tomarev SI. Rodent models of glaucoma. *Brain research bulletin* 2010; **81**: 349-58.
58. John SW, Smith RS, Savinova OV, Hawes NL, Chang B, Turnbull Det al. Essential iris atrophy, pigment dispersion, and glaucoma in DBA/2J mice. *Investigative ophthalmology & visual science* 1998; **39**: 951-62.
59. Schuettauf F, Rejdak R, Walski M, Frontczak-Baniewicz M, Voelker M, Blatsios Get al. Retinal neurodegeneration in the DBA/2J mouse-a model for ocular hypertension. *Acta neuropathologica* 2004; **107**: 352-8.
60. Chauhan BC, Pan J, Archibald ML, LeVatte TL, Kelly ME, Tremblay F. Effect of intraocular pressure on optic disc topography, electroretinography, and axonal loss in a chronic pressure-induced rat model of optic nerve damage. *Invest Ophthalmol Vis Sci* 2002; **43**: 2969-76.
61. Cohan BE, Peach AC, Jokelainen PT, Bohr DF. Optic disc imaging in conscious rats and mice. *Invest Ophthalmol Vis Sci* 2003; **44**: 160-3.
62. Neufeld AH, Sawada A, Becker B. Inhibition of nitric-oxide synthase 2 by aminoguanidine provides neuroprotection of retinal ganglion cells in a rat model of chronic glaucoma. *Proc Natl Acad Sci U S A* 1999; **96**: 9944-8.
63. John SW, Smith RS, Savinova OV, Hawes NL, Chang B, Turnbull Det al. Essential iris atrophy, pigment dispersion, and glaucoma in DBA/2J mice. *Invest Ophthalmol Vis Sci* 1998; **39**: 951-62.
64. Cioffi GA, Sullivan P. The effect of chronic ischemia on the primate optic nerve. *Eur J Ophthalmol* 1999; **9 Suppl 1**: S34-6.
65. Orgul S, Cioffi GA, Wilson DJ, Bacon DR, Van Buskirk EM. An endothelin-1 induced model of optic nerve ischemia in the rabbit. *Invest Ophthalmol Vis Sci* 1996; **37**: 1860-9.



66. Quigley HA, Hohman RM. Laser energy levels for trabecular meshwork damage in the primate eye. *Invest Ophthalmol Vis Sci* 1983; **24**: 1305-7.

**Figure 1**



**Figure Legend**

The classification of glaucoma (see text for details)

